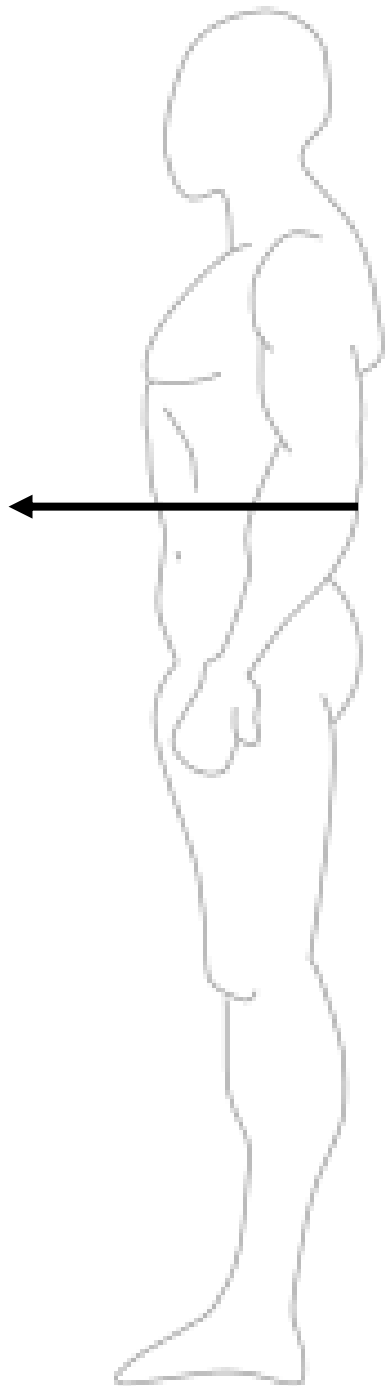


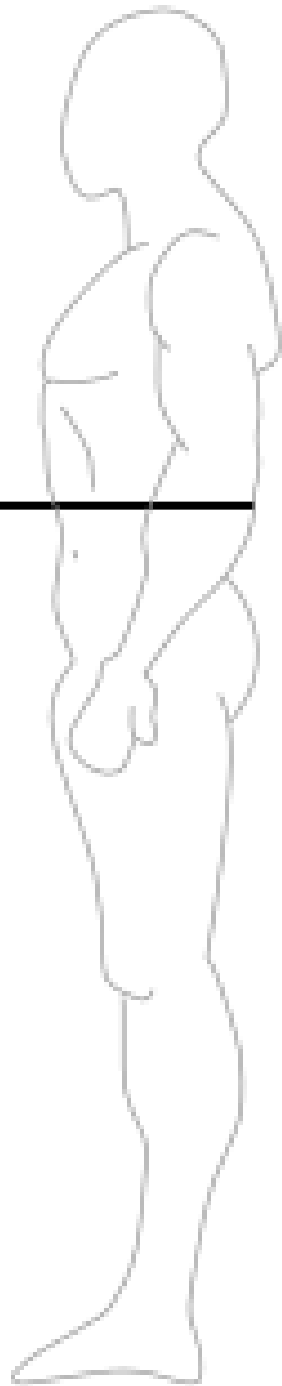
Directional Terminology

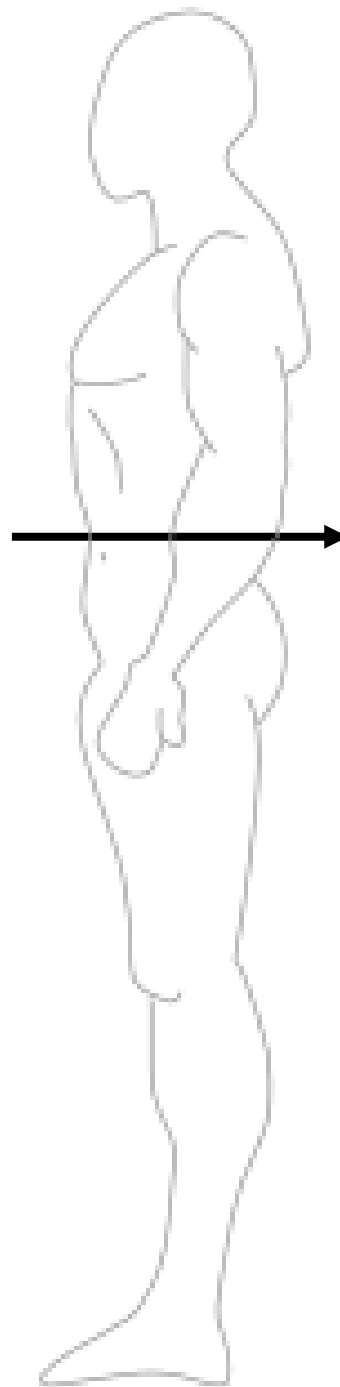
Name the following anatomical directional terms as indicated by the arrows:



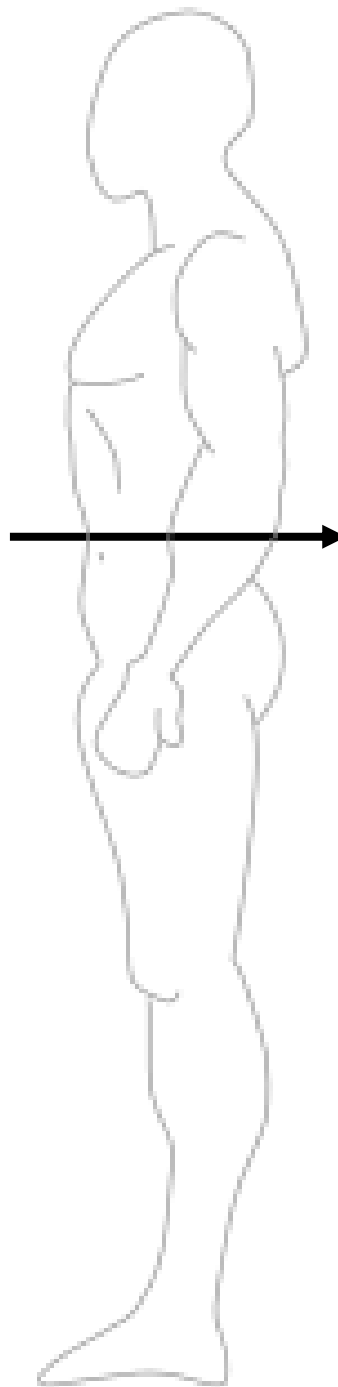
*scroll to the next slide to check your answer

Anterior/Ventral

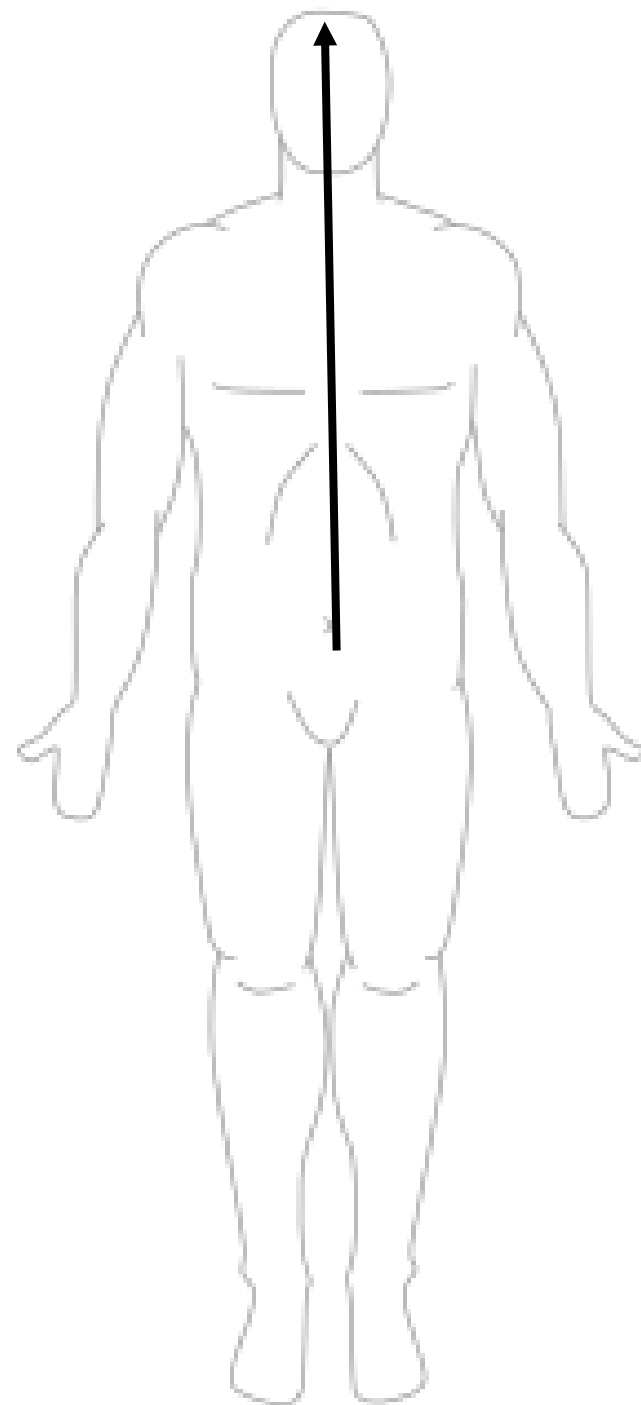




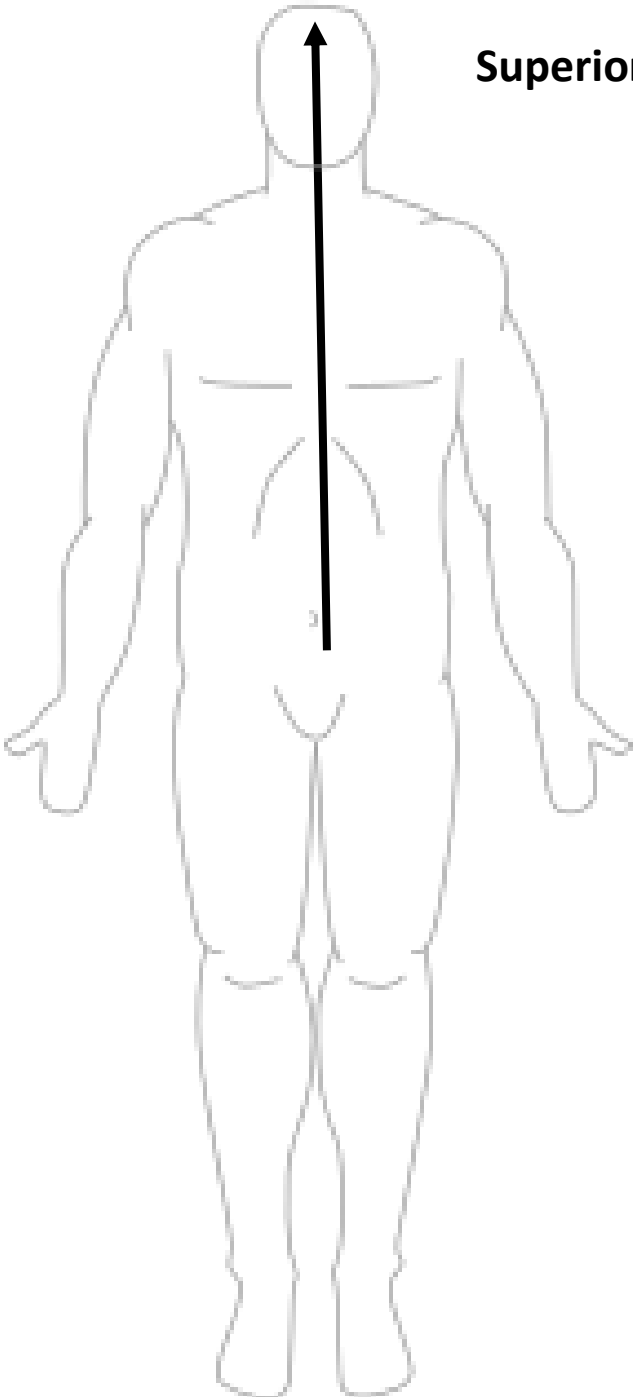
*scroll to the next slide to check your answer



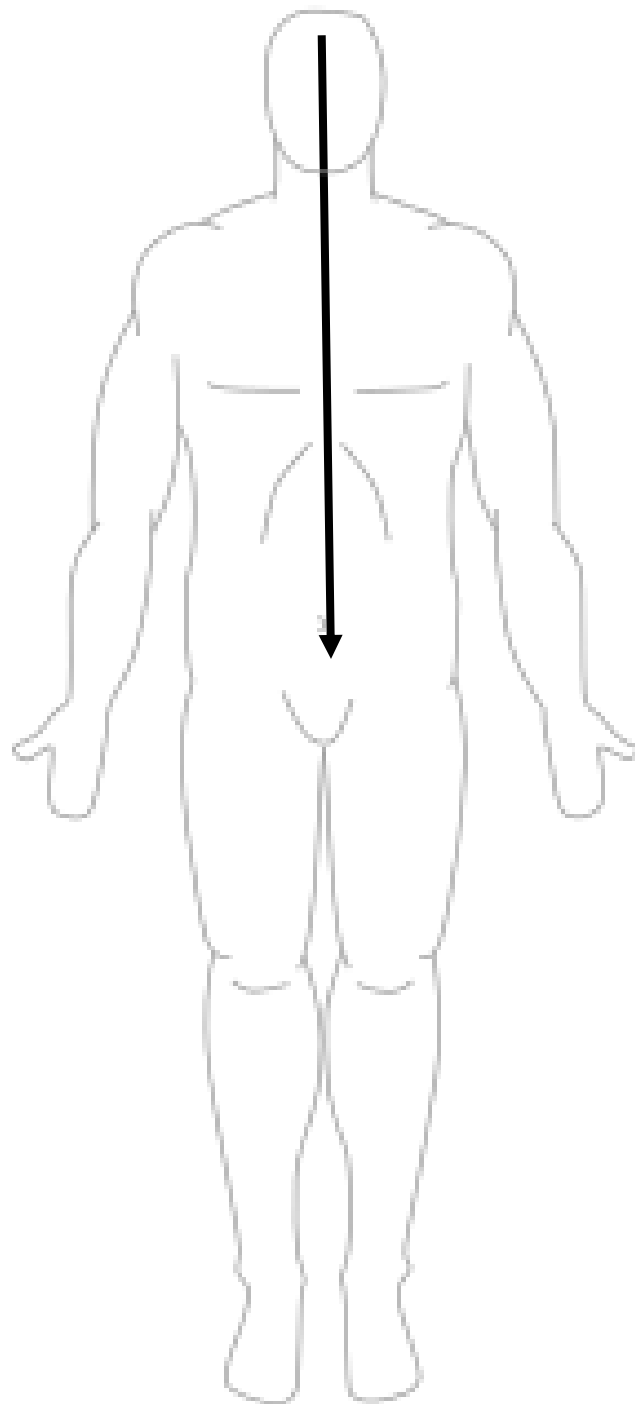
Posterior/Dorsal



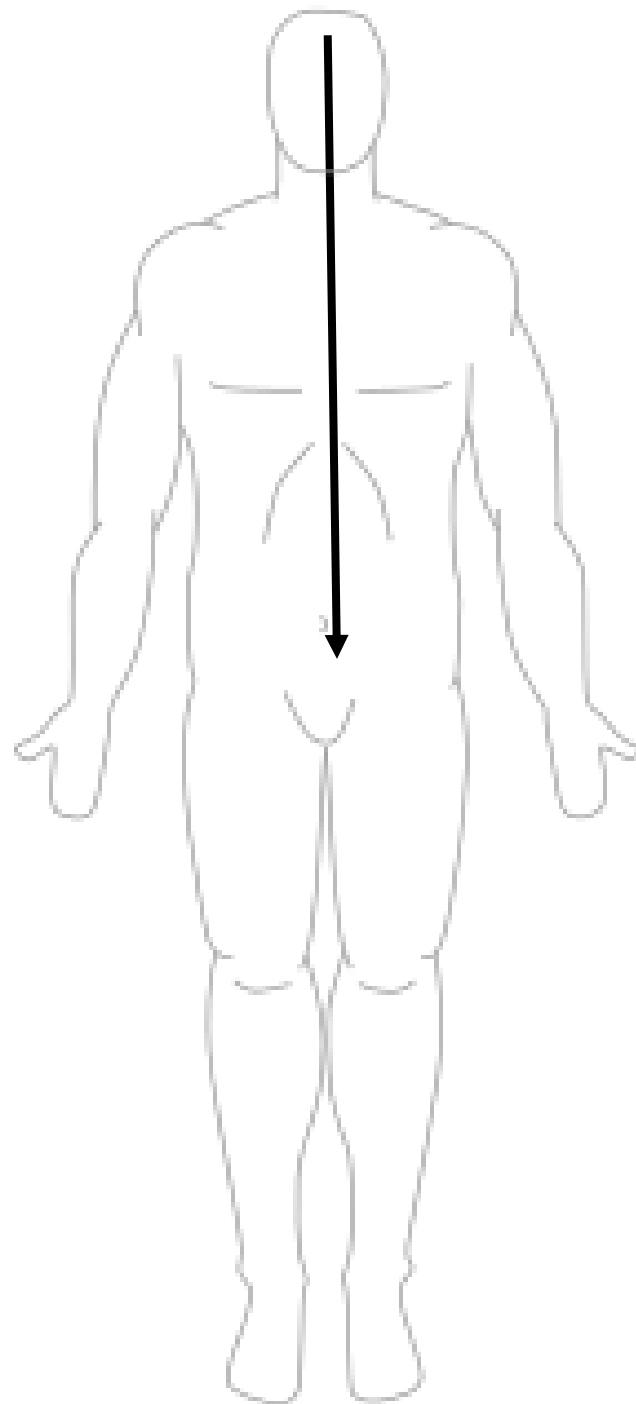
*scroll to the next slide to check your answer



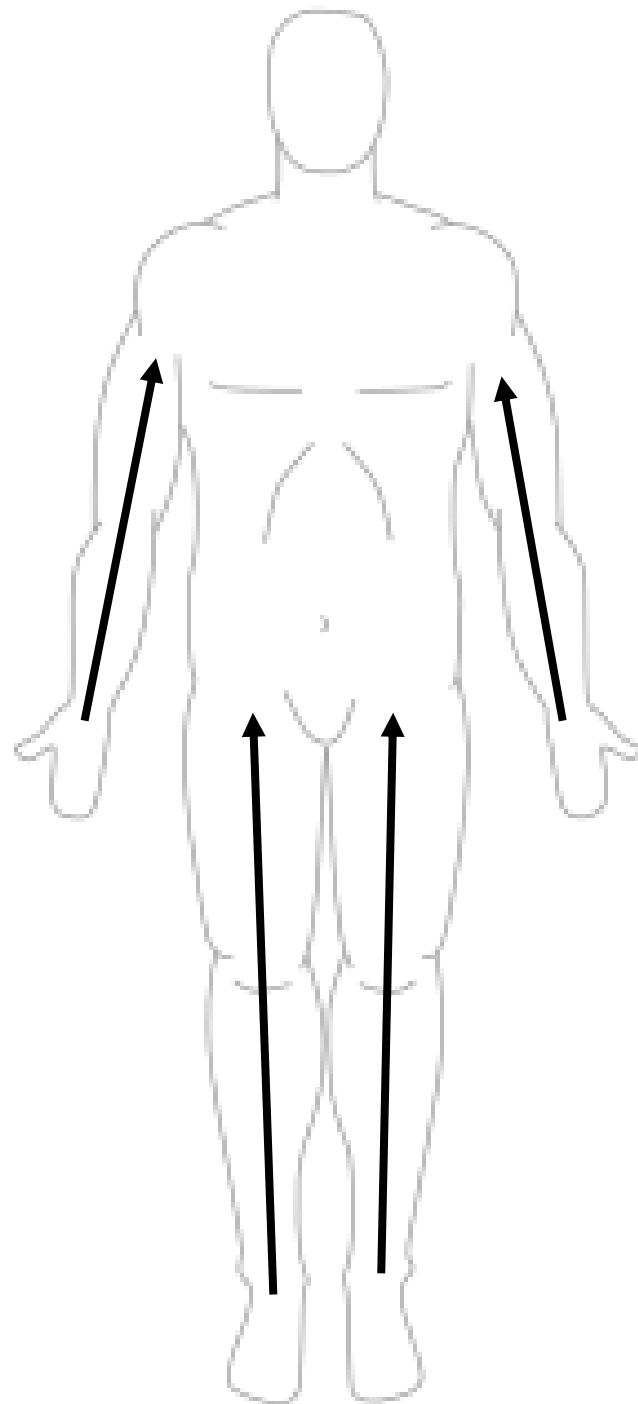
Superior (cranial/cephalic)



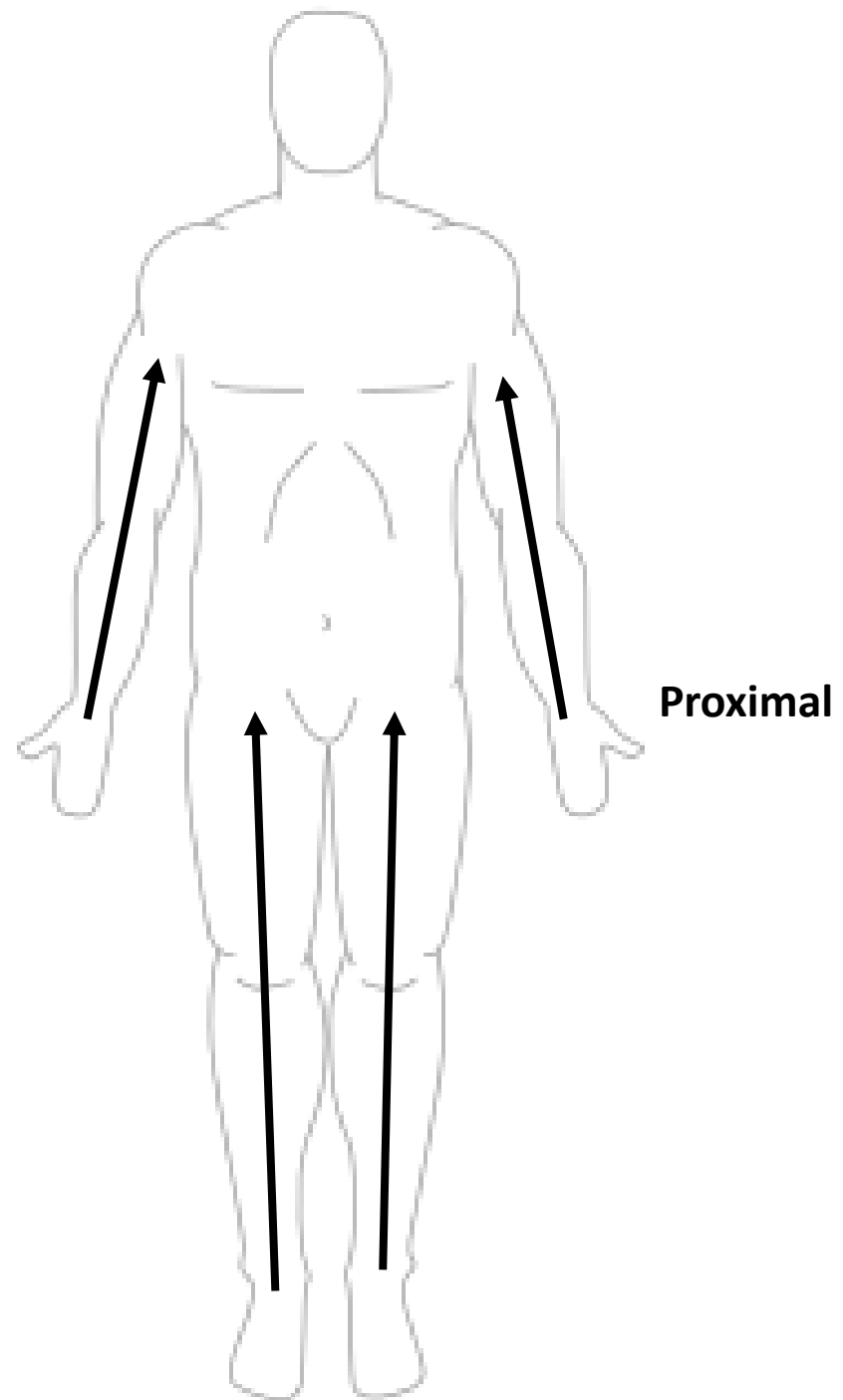
*scroll to the next slide to check your answer

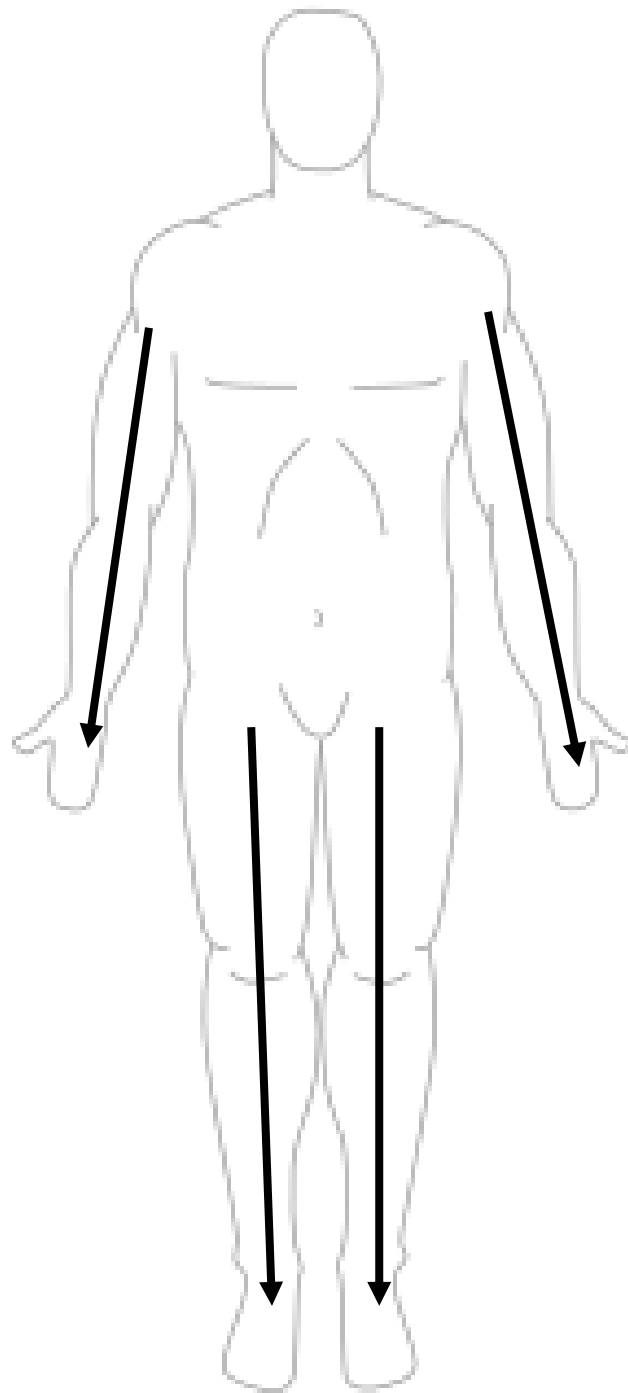


Inferior (caudal)

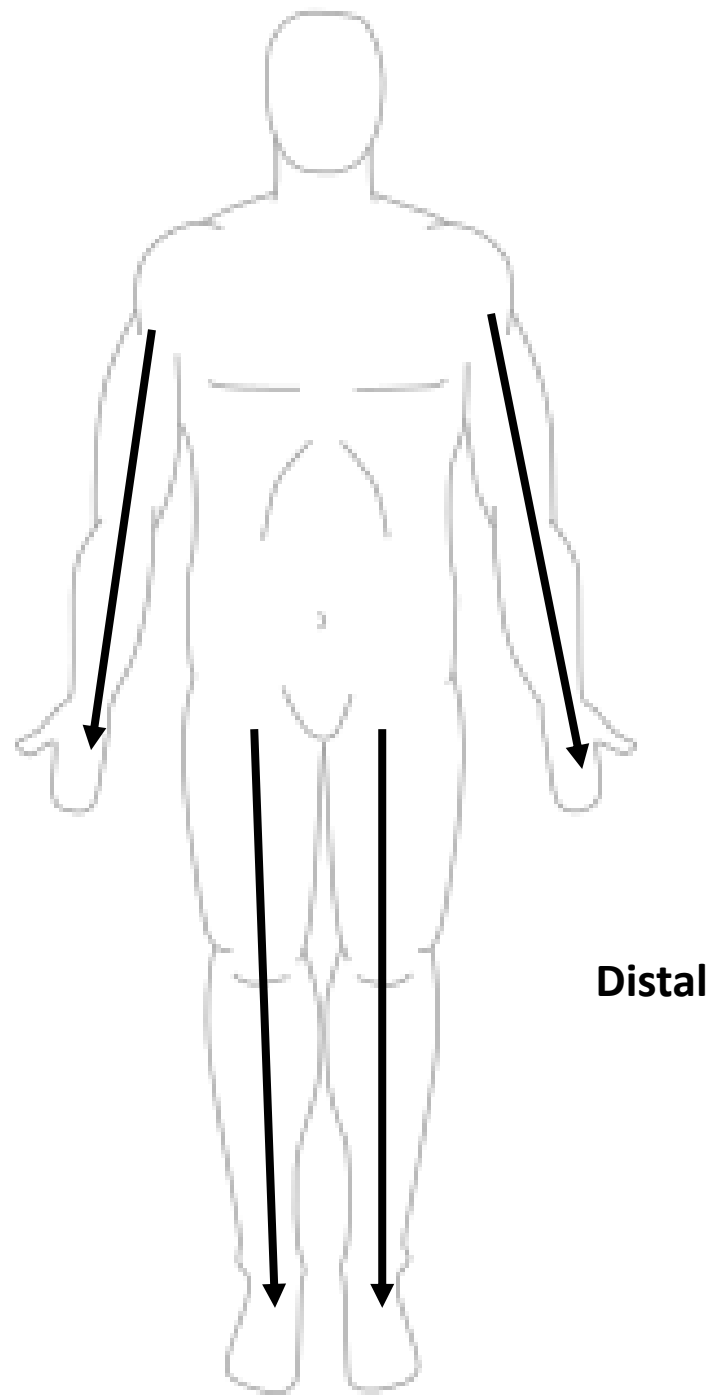


*scroll to the next slide to check your answer

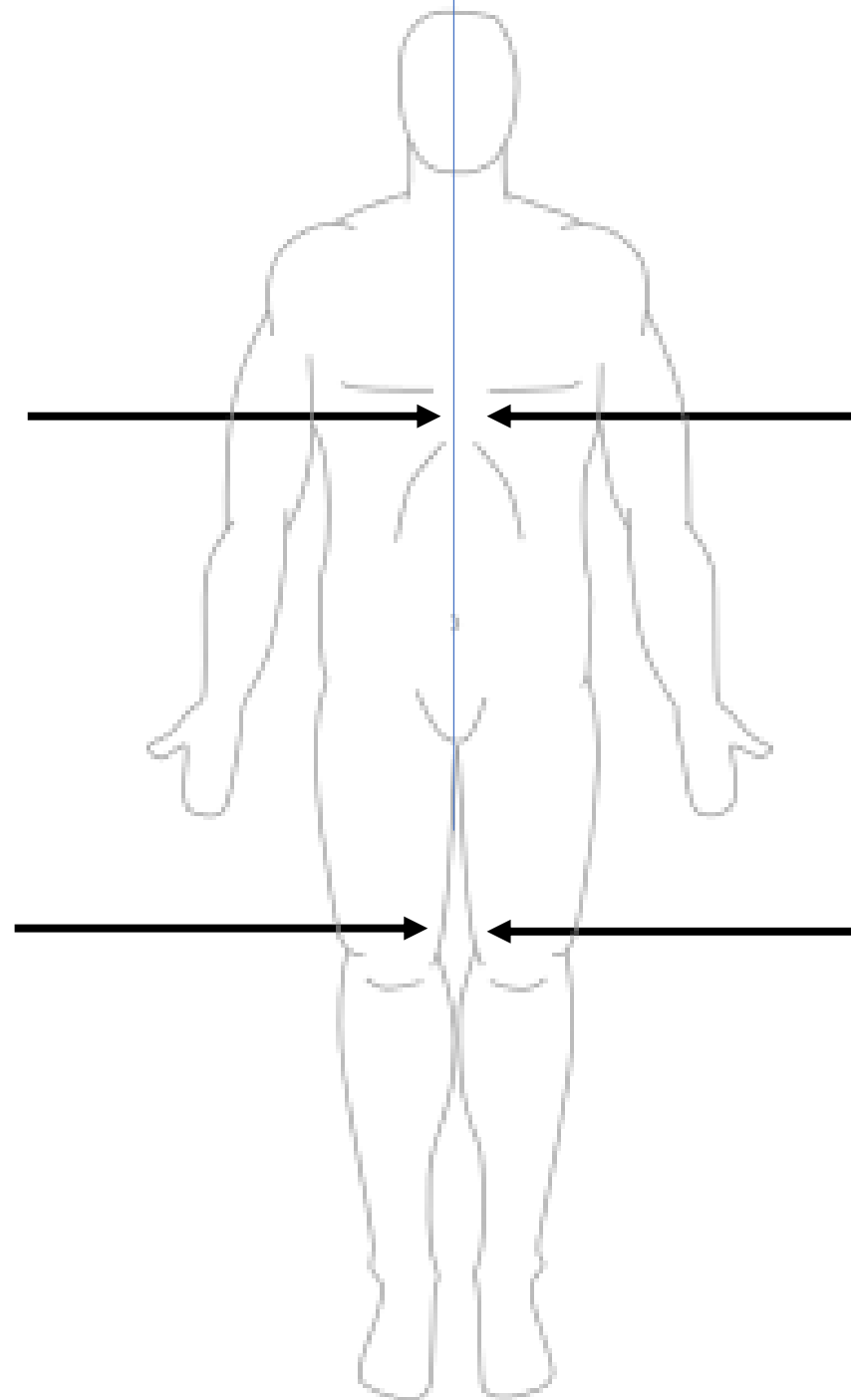




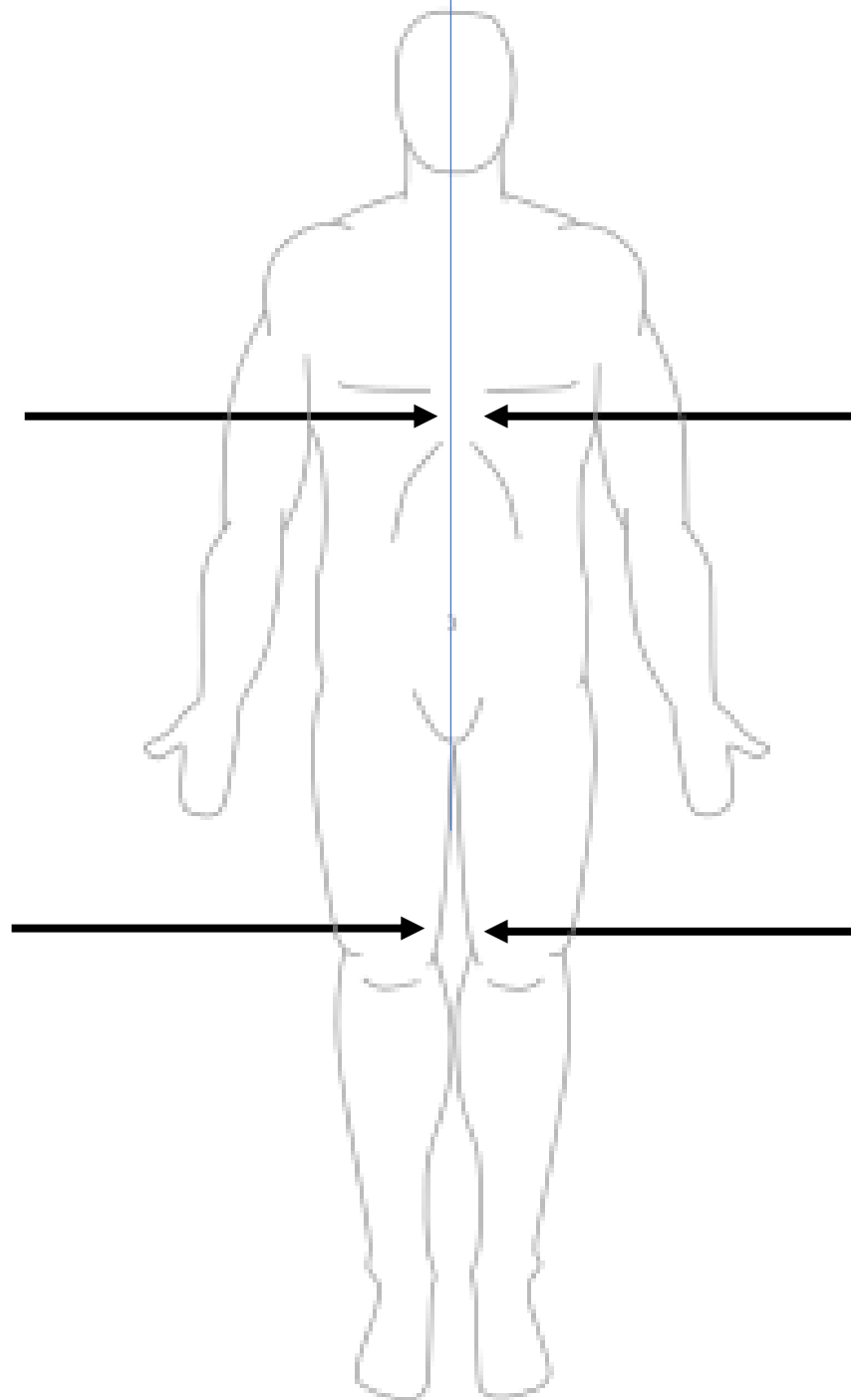
*scroll to the next slide to check your answer



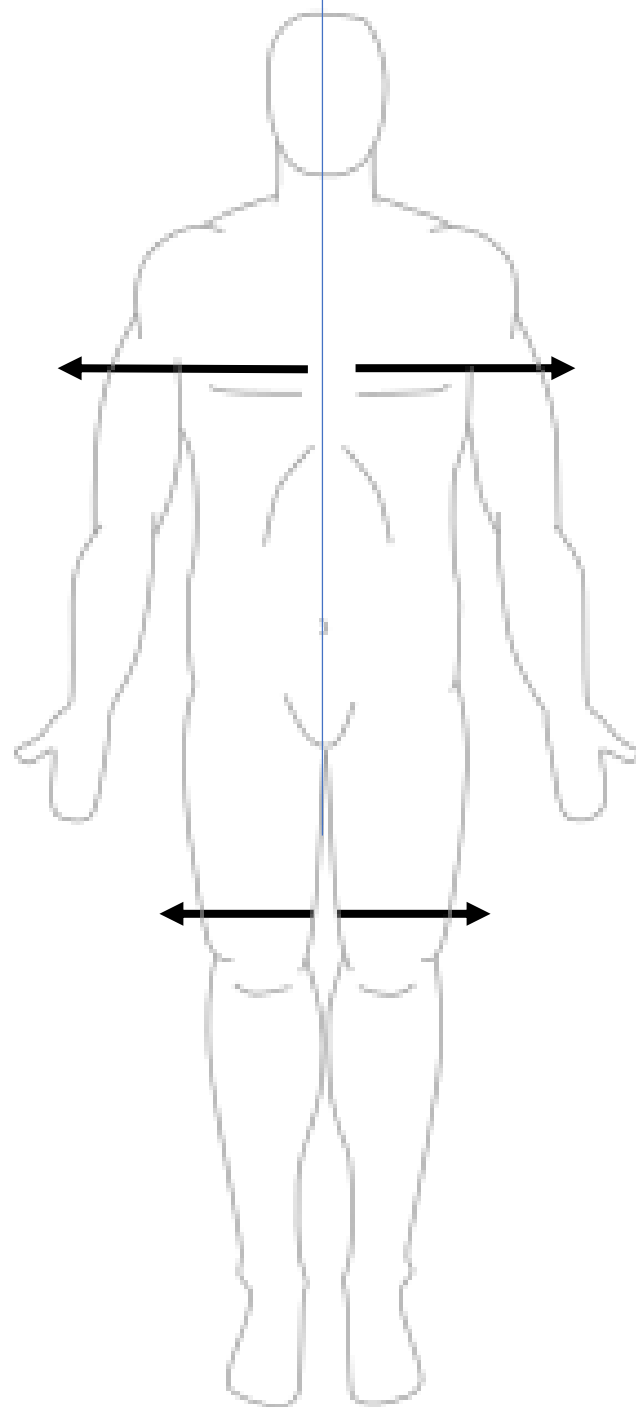
Distal



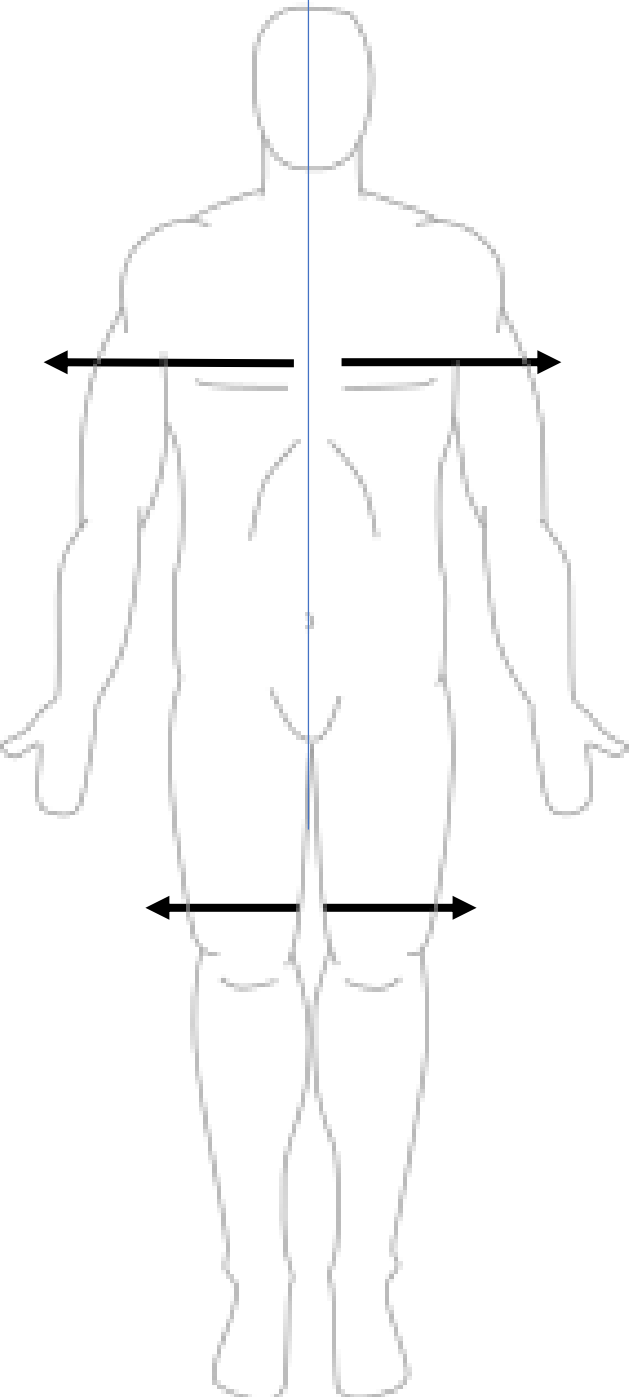
*scroll to the next slide to check your answer



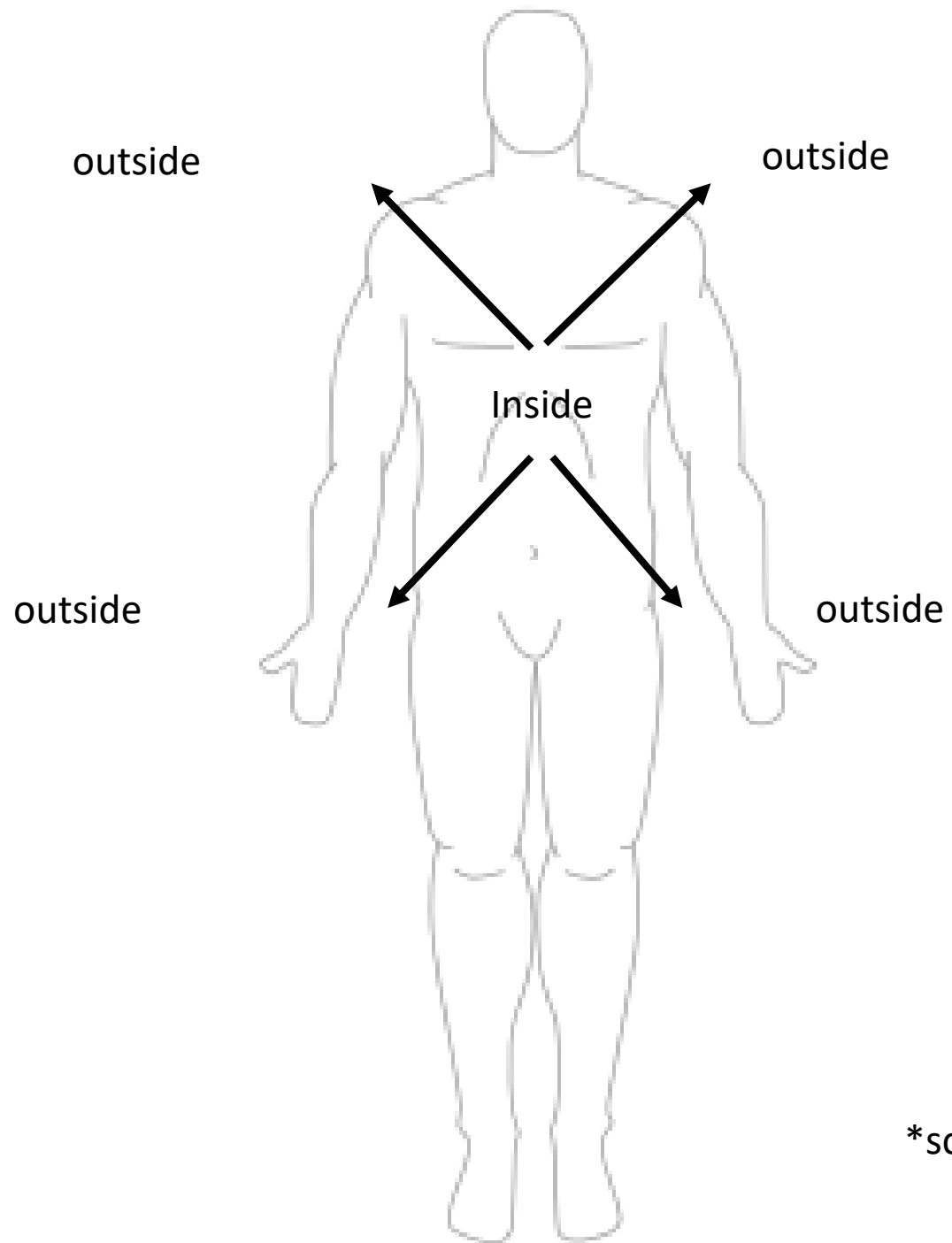
Medial



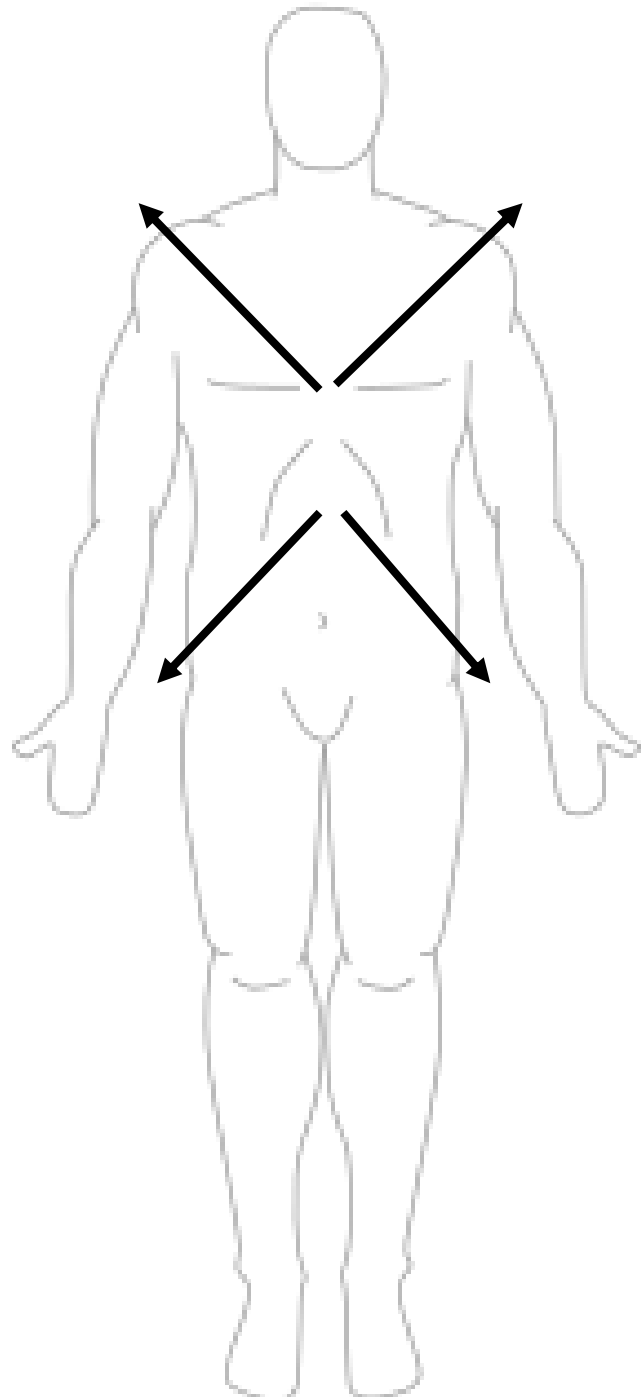
*scroll to the next slide to check your answer



Lateral



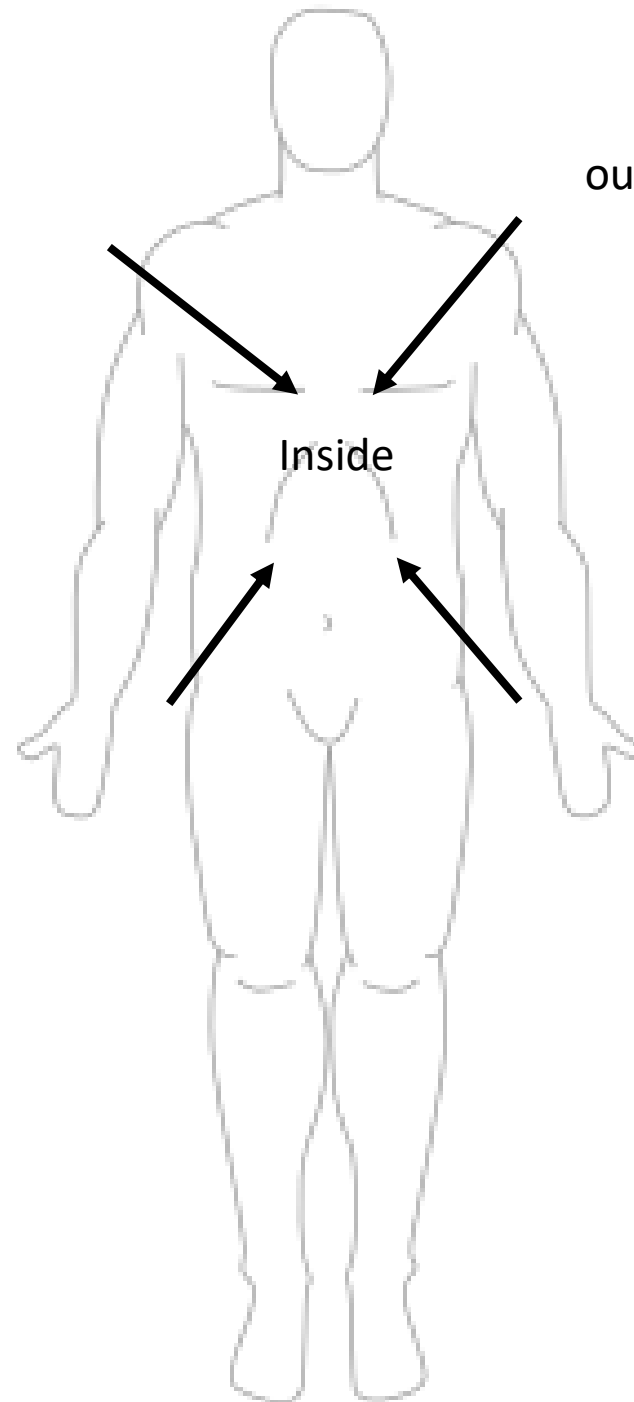
*scroll to the next slide to check your answer



Superficial/External

outside

outside

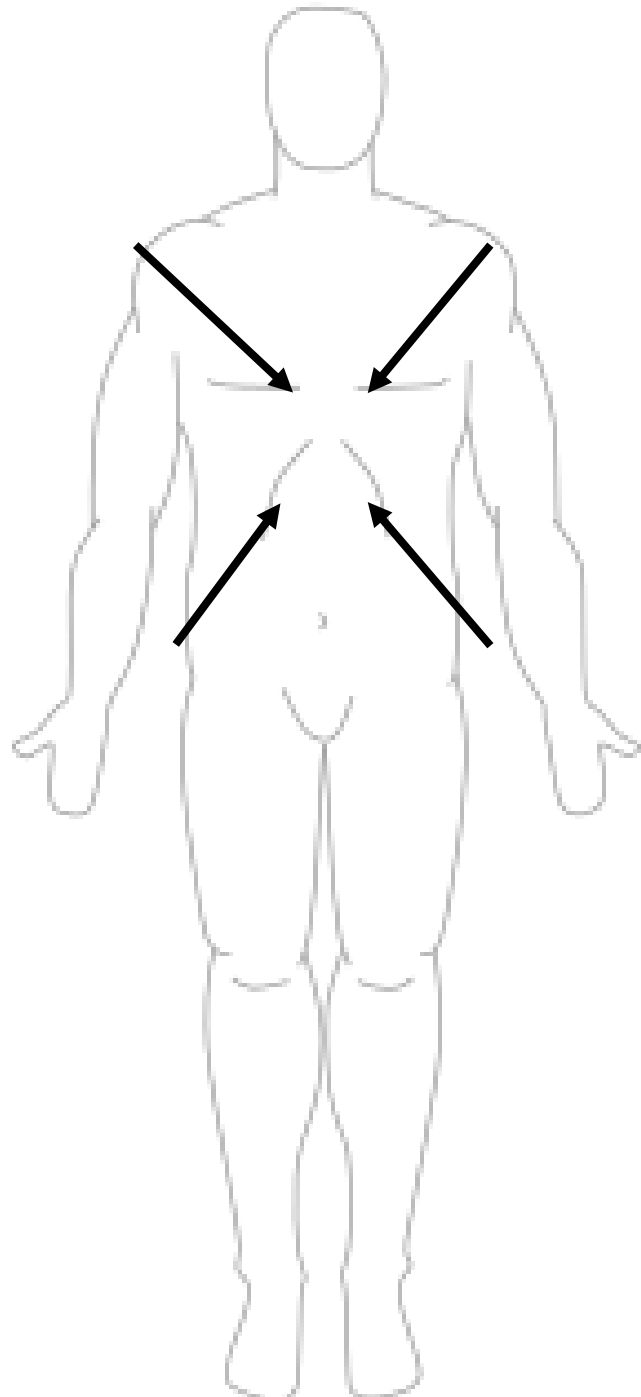


Inside

outside

outside

*scroll to the next slide to check your answer



Deep/Internal