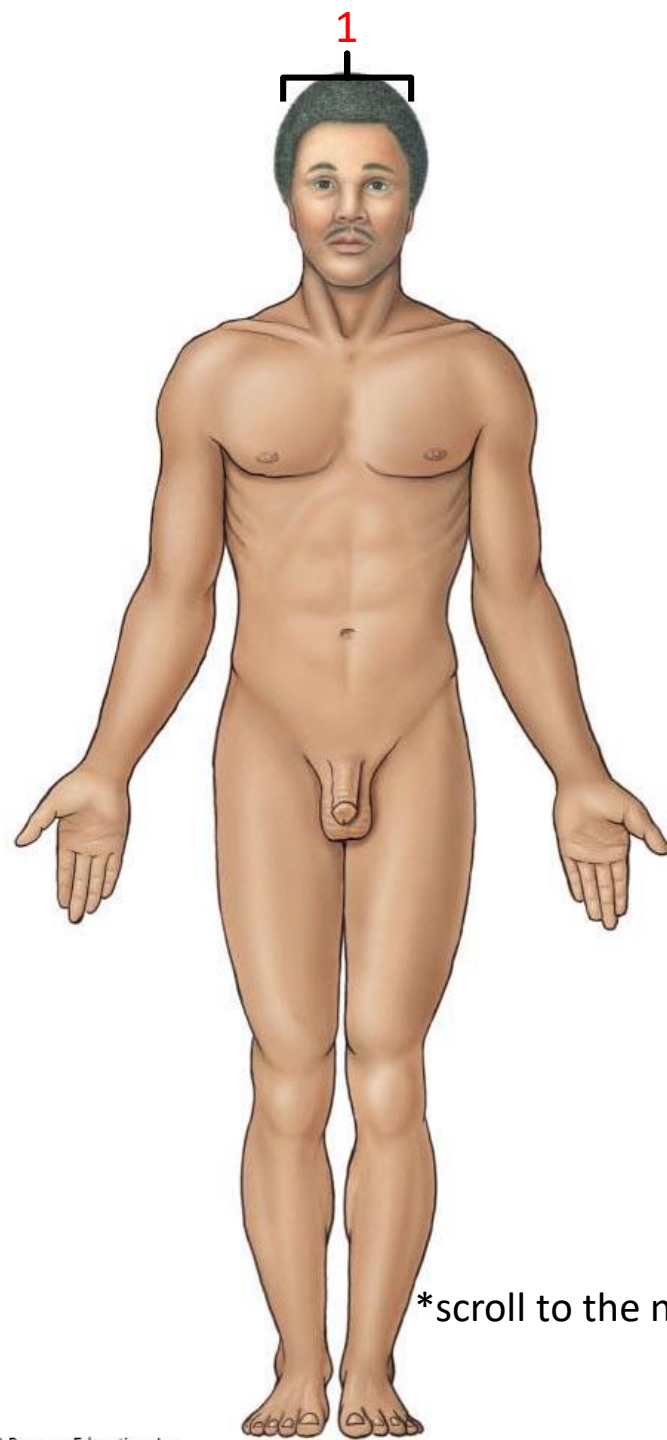


# **Anatomical Terminology**

## **Practice Exam #1**

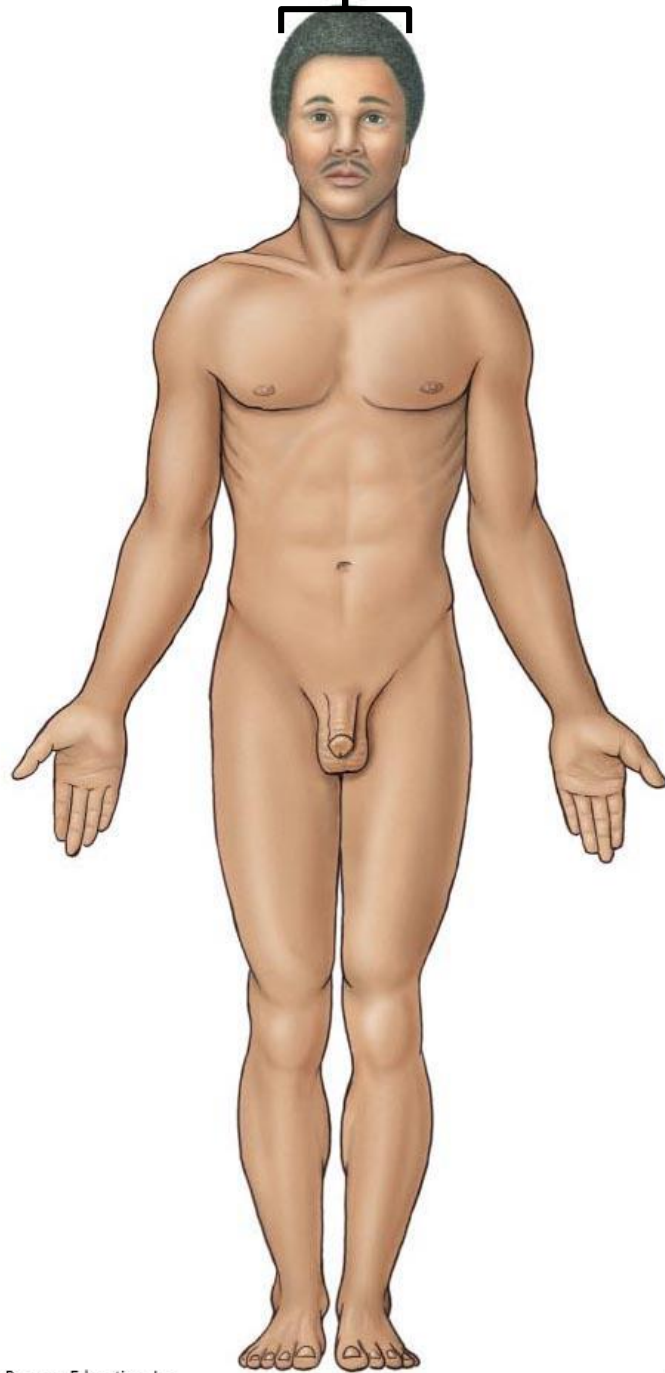
\*For best results on these practice exams, write your answers on paper before scrolling to see the correct answer and make sure to check your spelling!

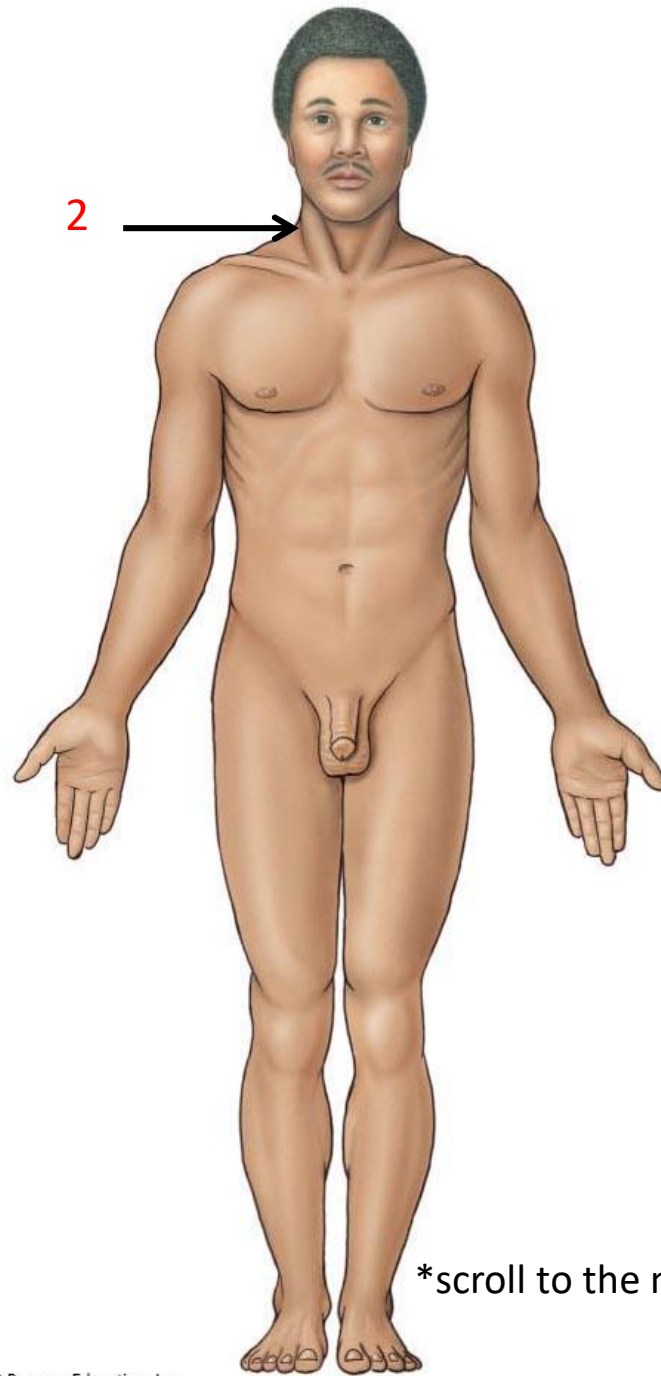
Using proper anatomical terminology, name the following body regions and landmarks:



\*scroll to the next slide to check your answer

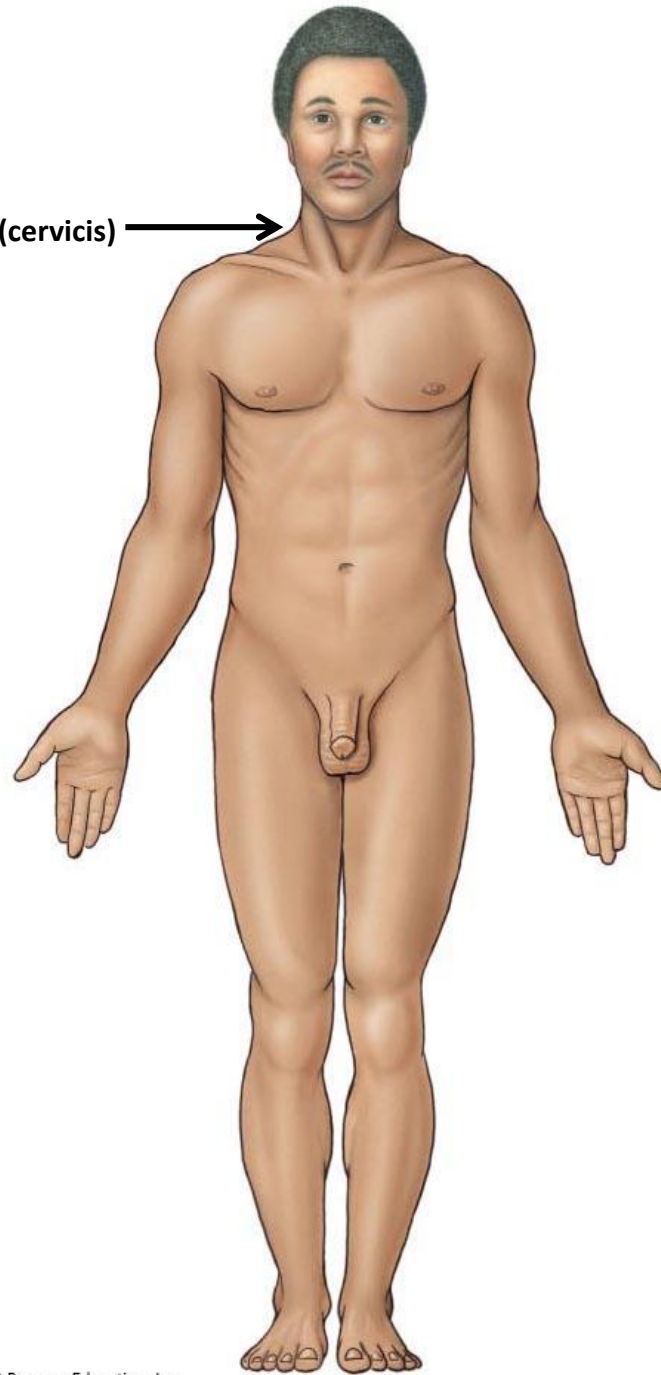
Cranial (cranium)



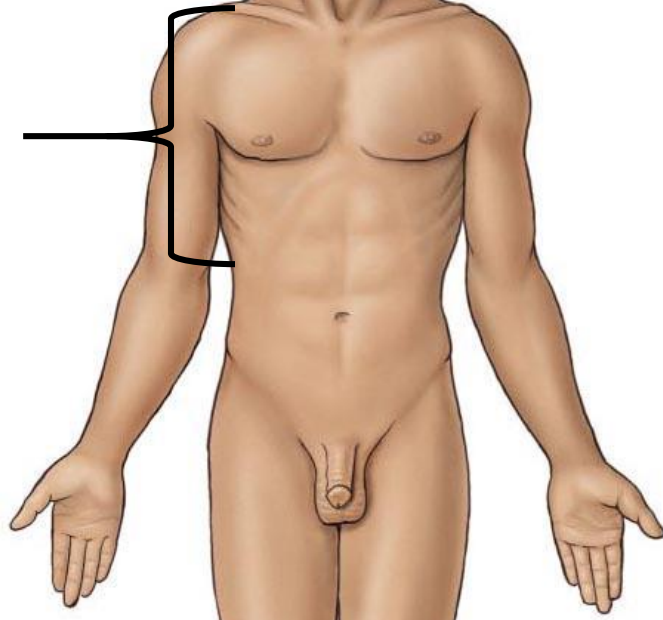


\*scroll to the next slide to check your answer

Cervical (cervicis) →

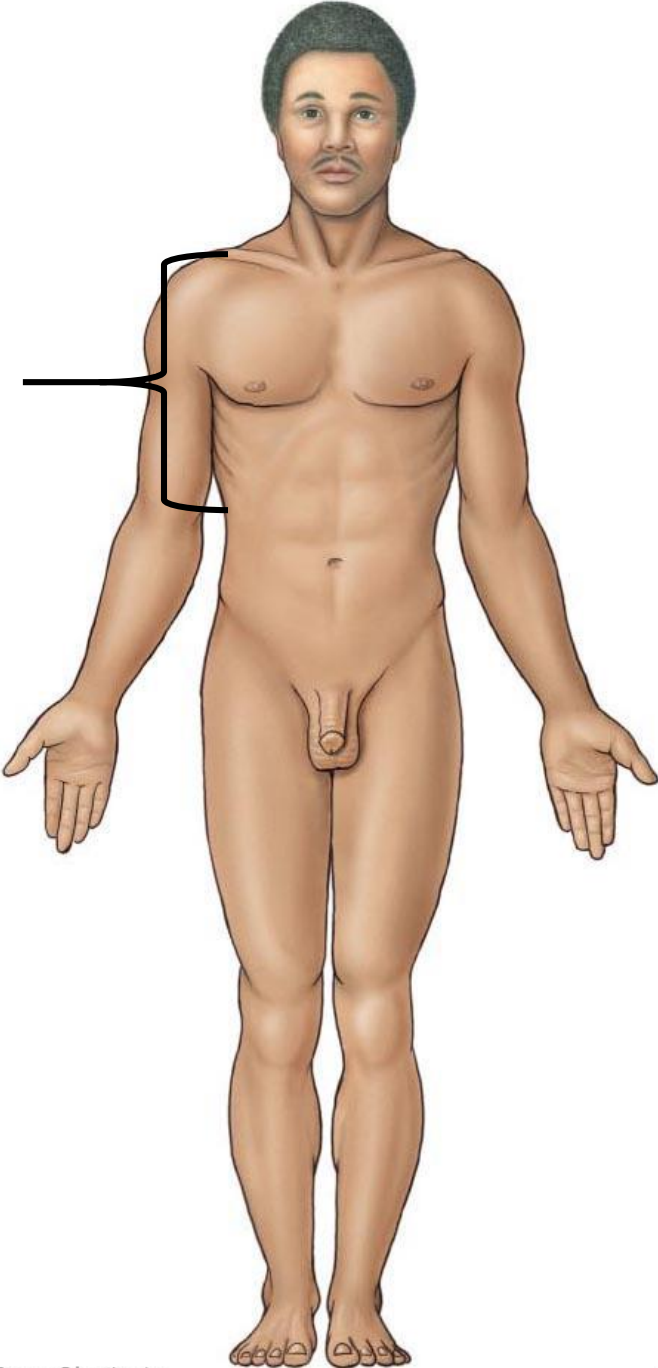


3

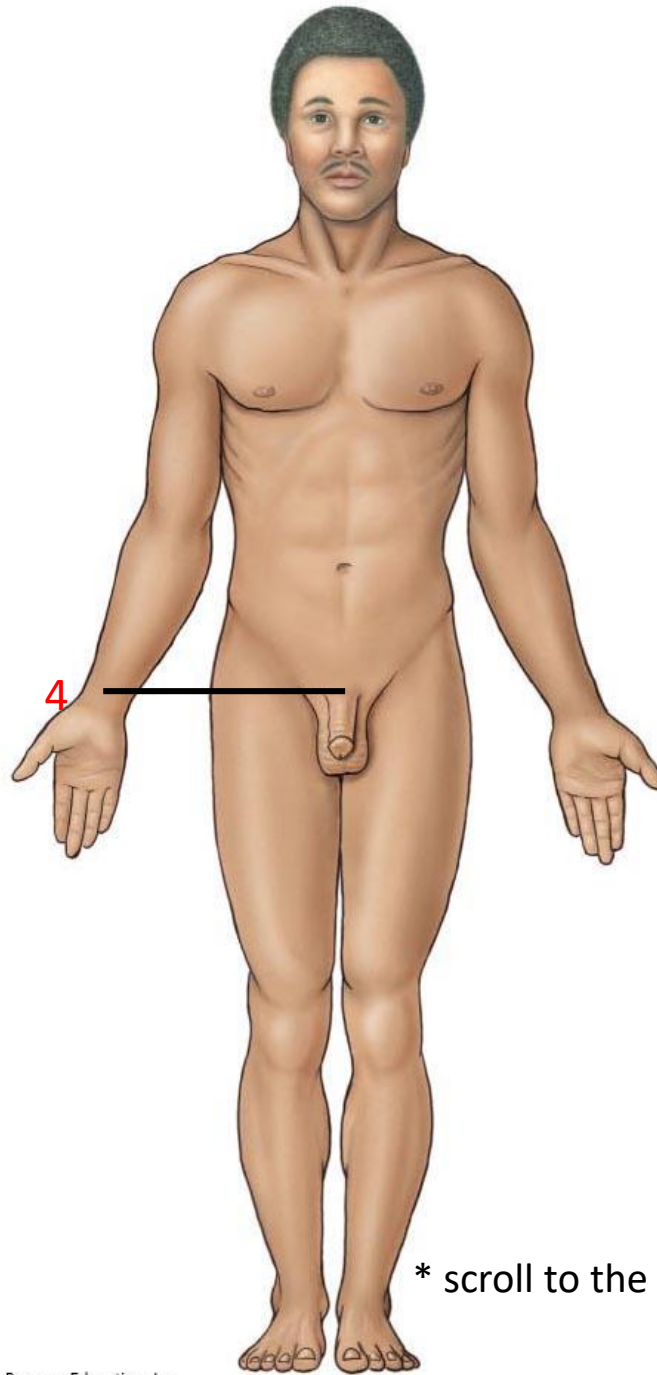


\*scroll to the next slide to check your answer

**Thoracic (thorax)**

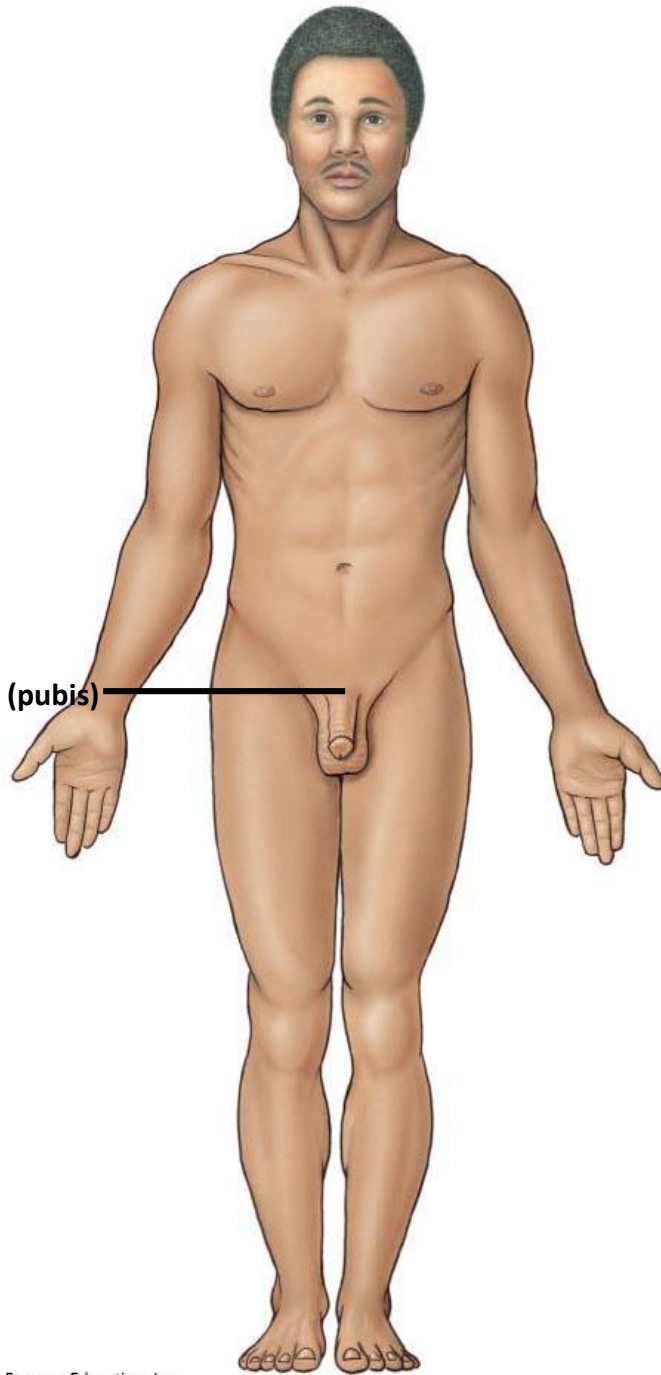


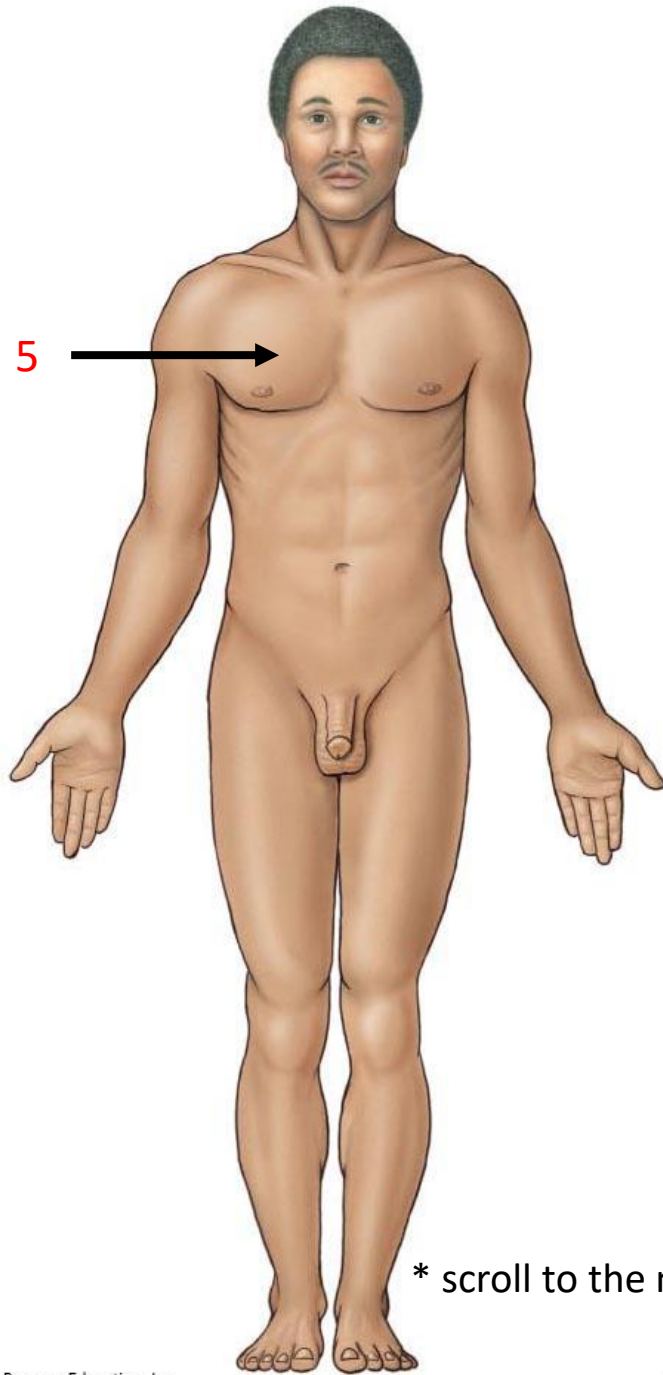




\* scroll to the next slide to check your answer

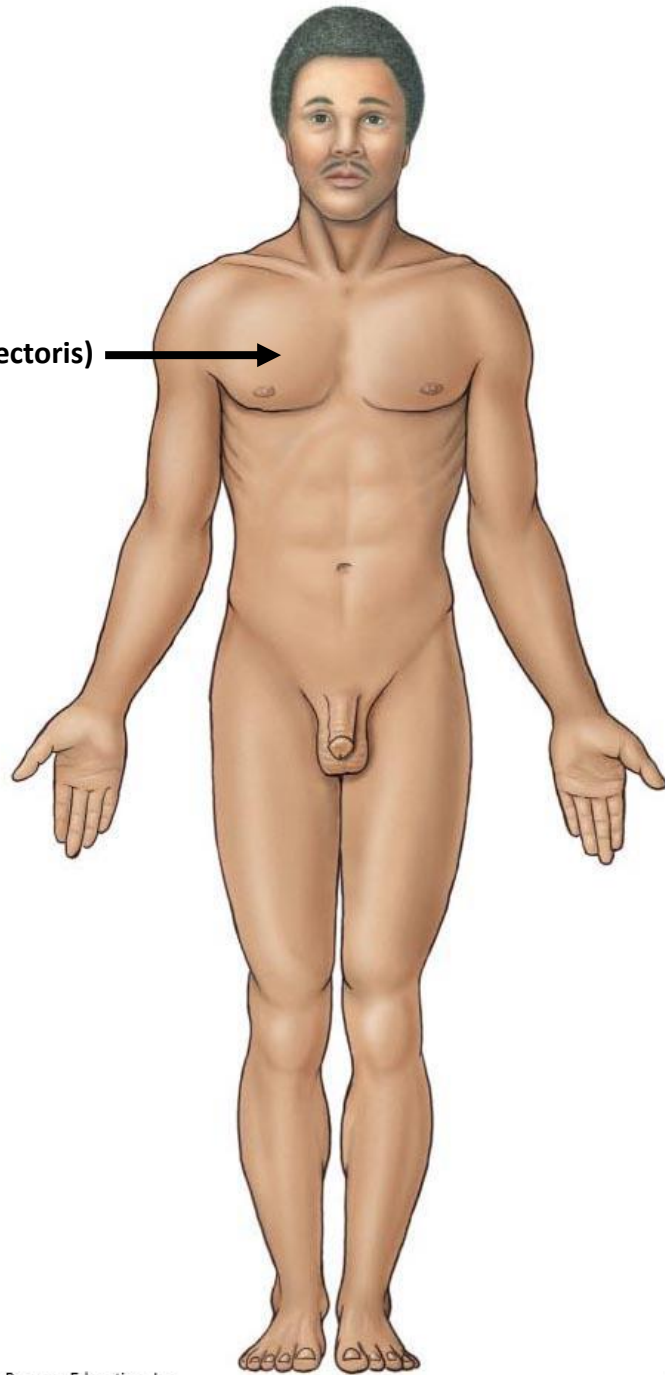
**Pubic (pubis)**

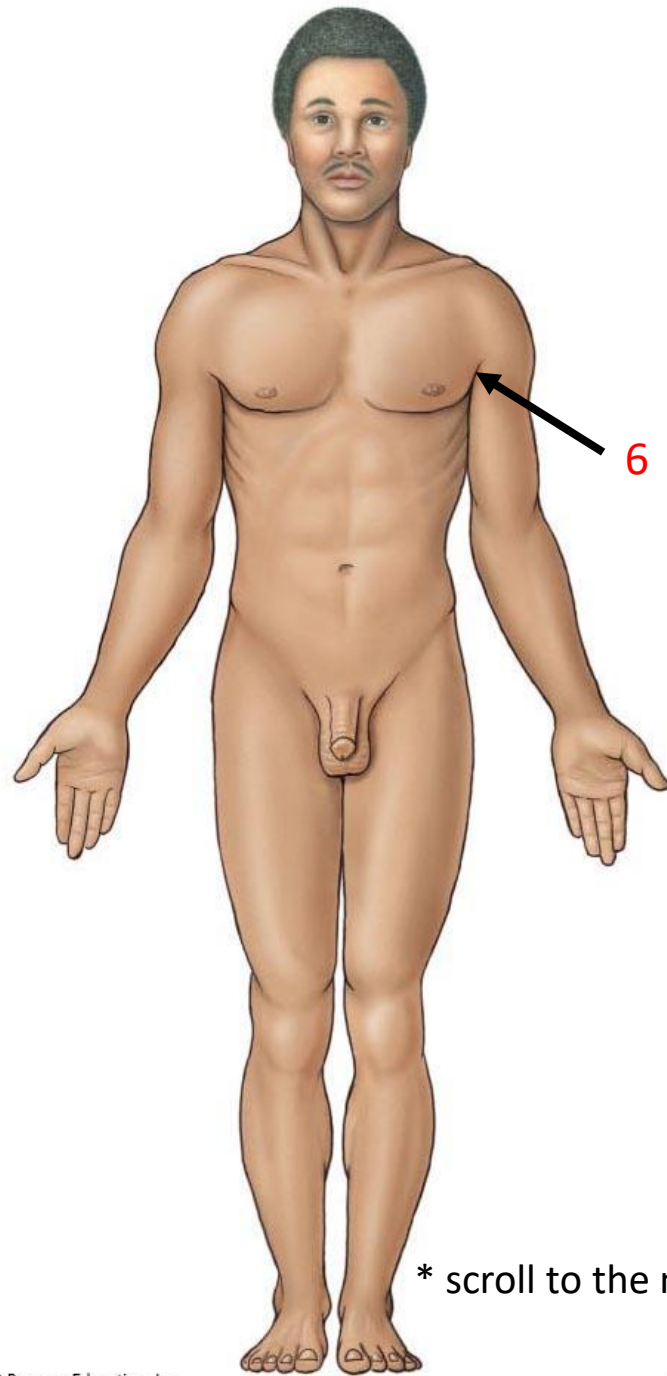




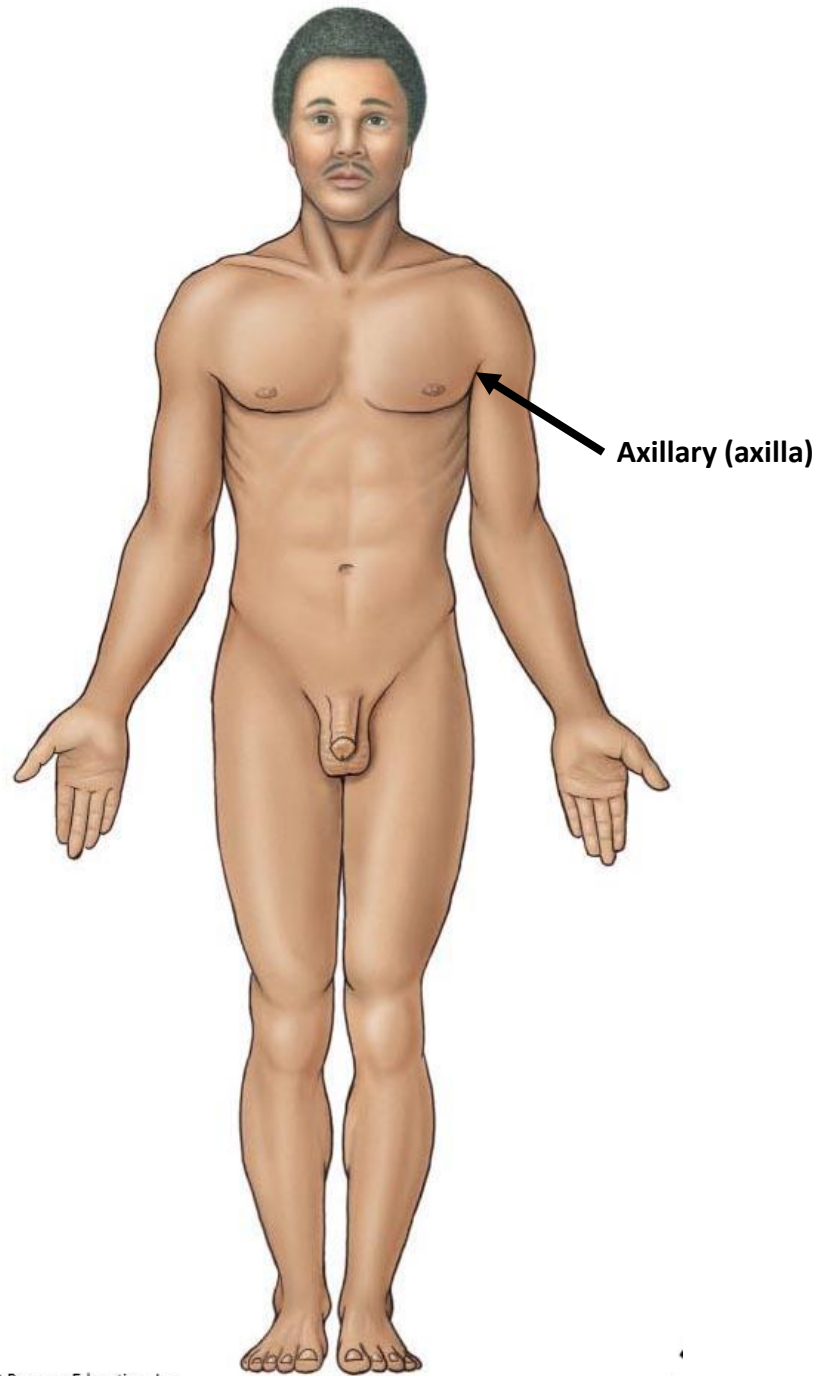
\* scroll to the next slide to check your answer

**Pectoral (pectoris)** →

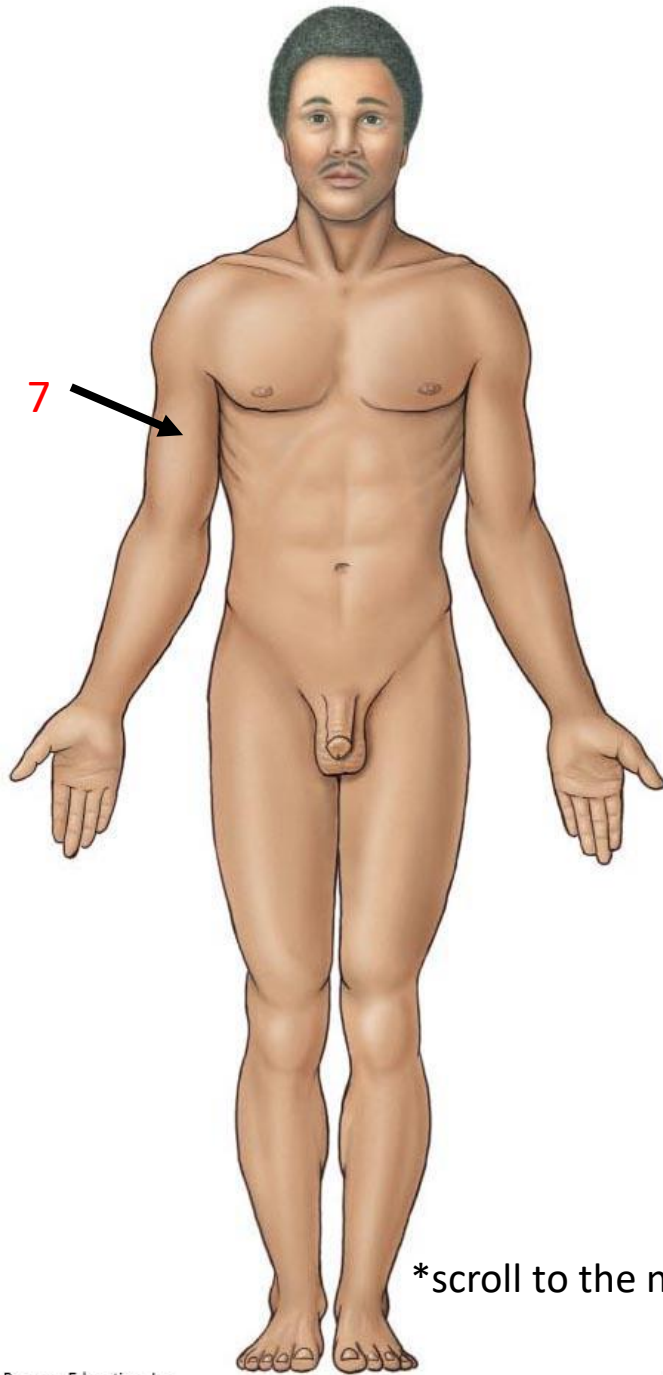




\* scroll to the next slide to check your answer

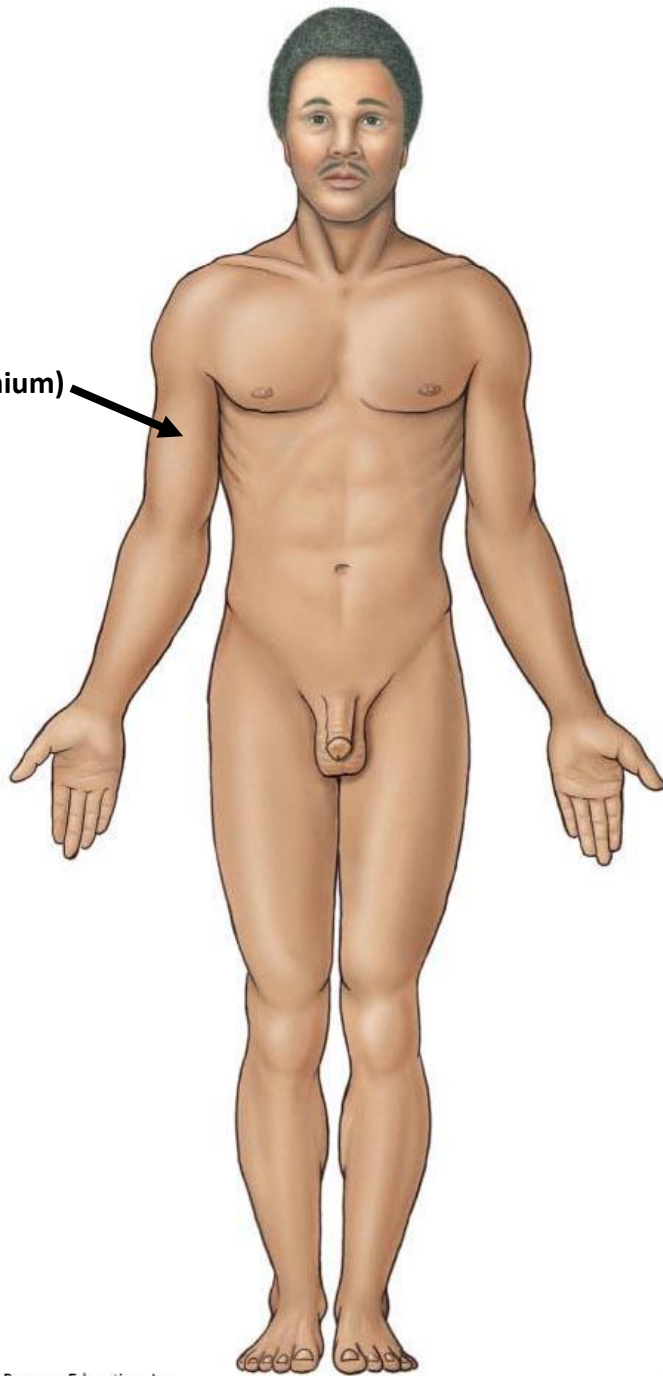


**Axillary (axilla)**

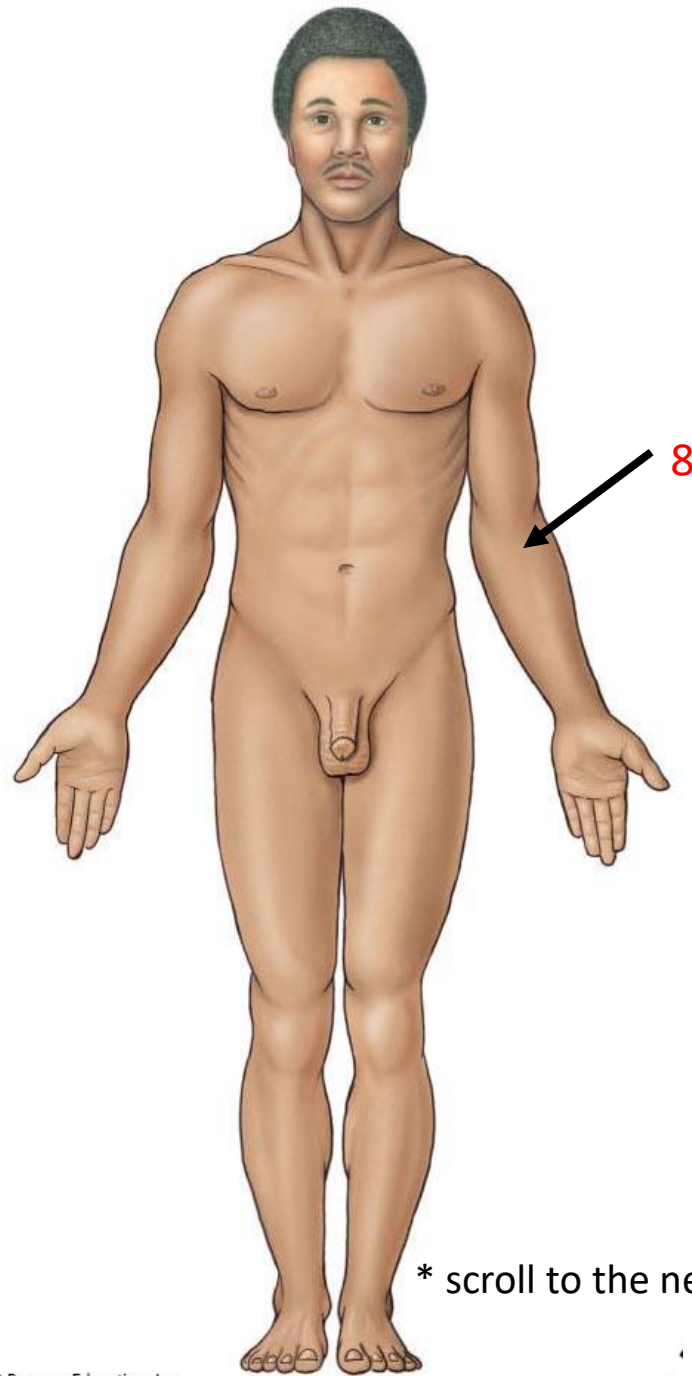


\*scroll to the next slide to check your answer

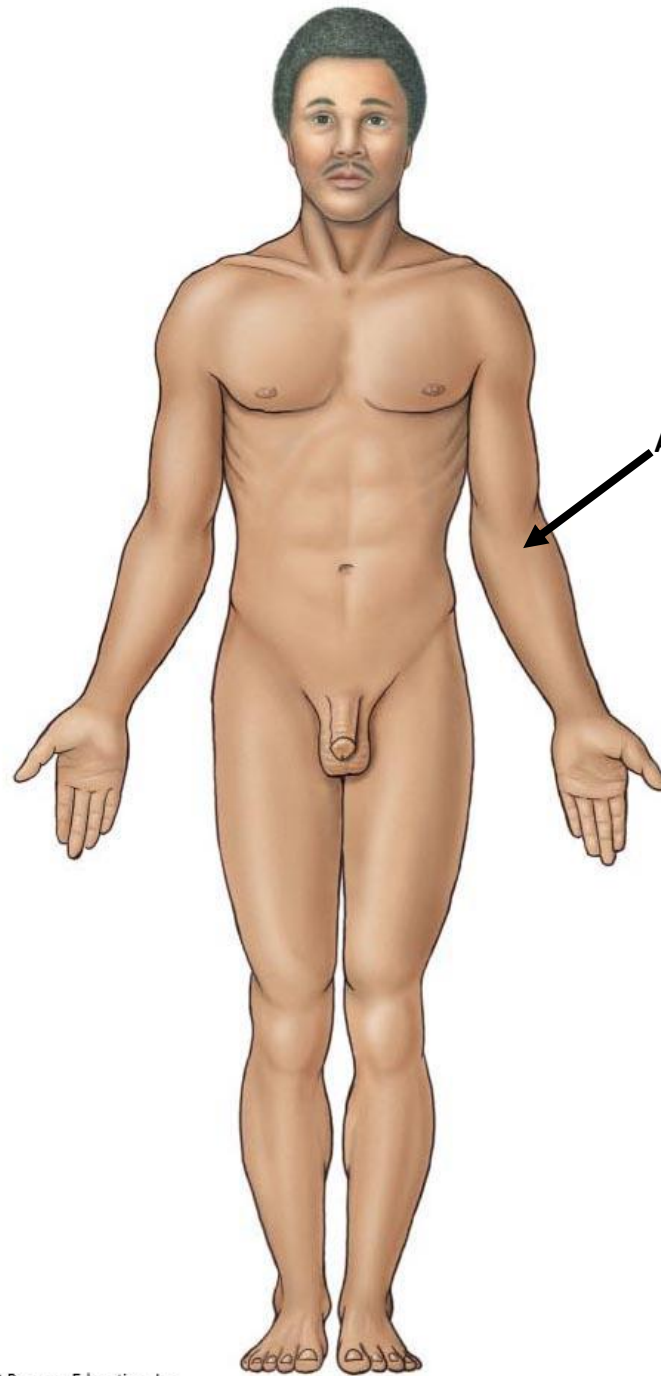
**Brachial (brachium)**



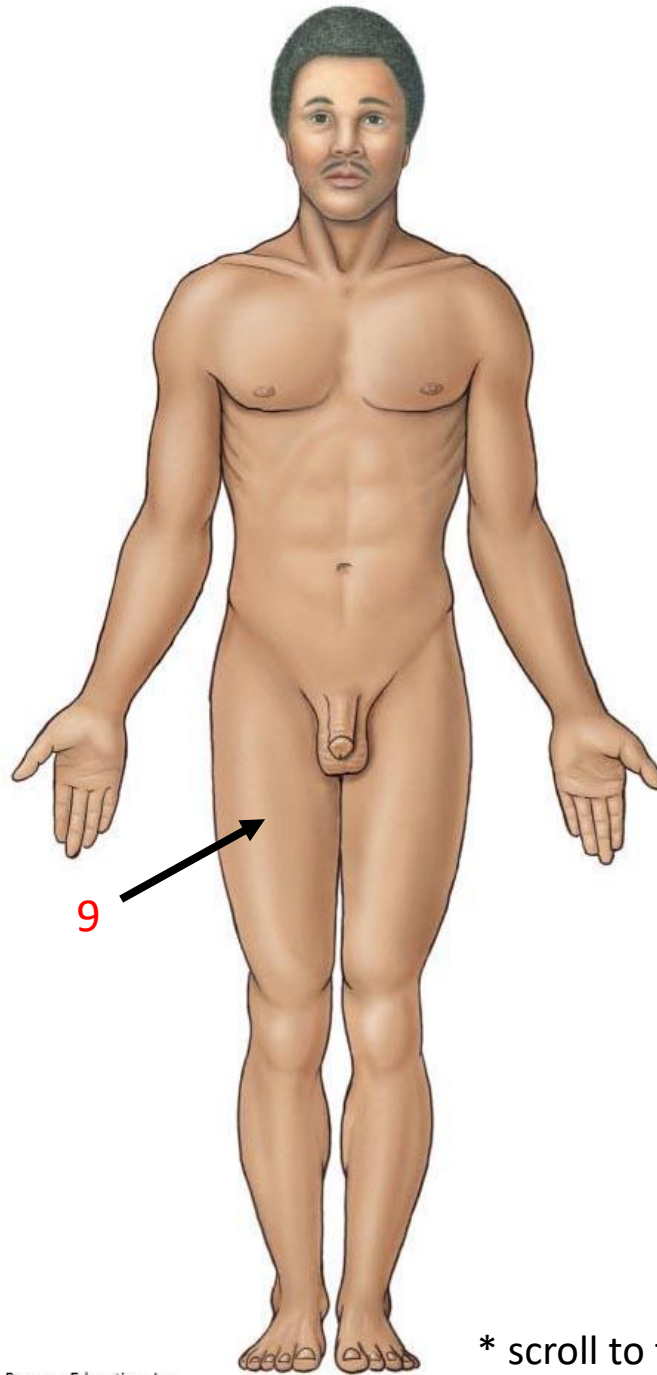


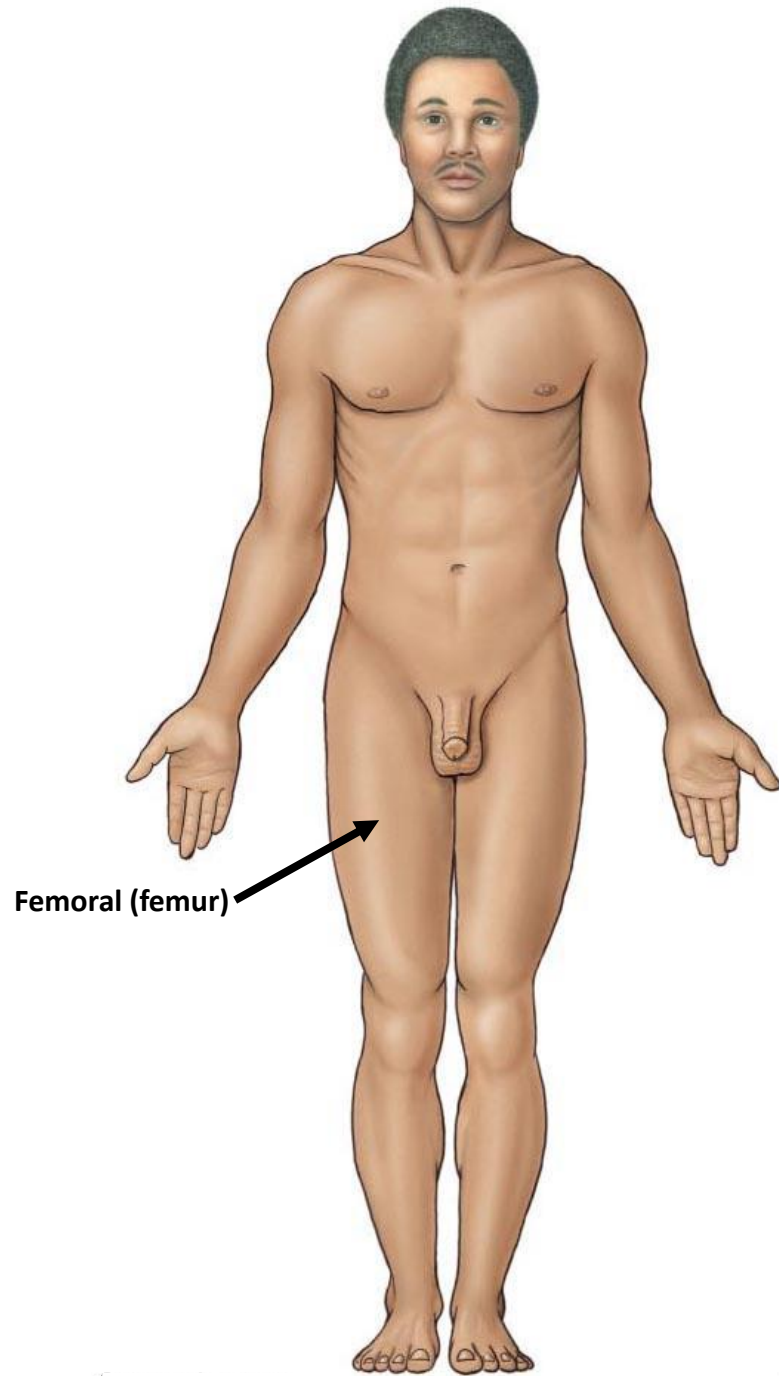


\* scroll to the next slide to check your answer

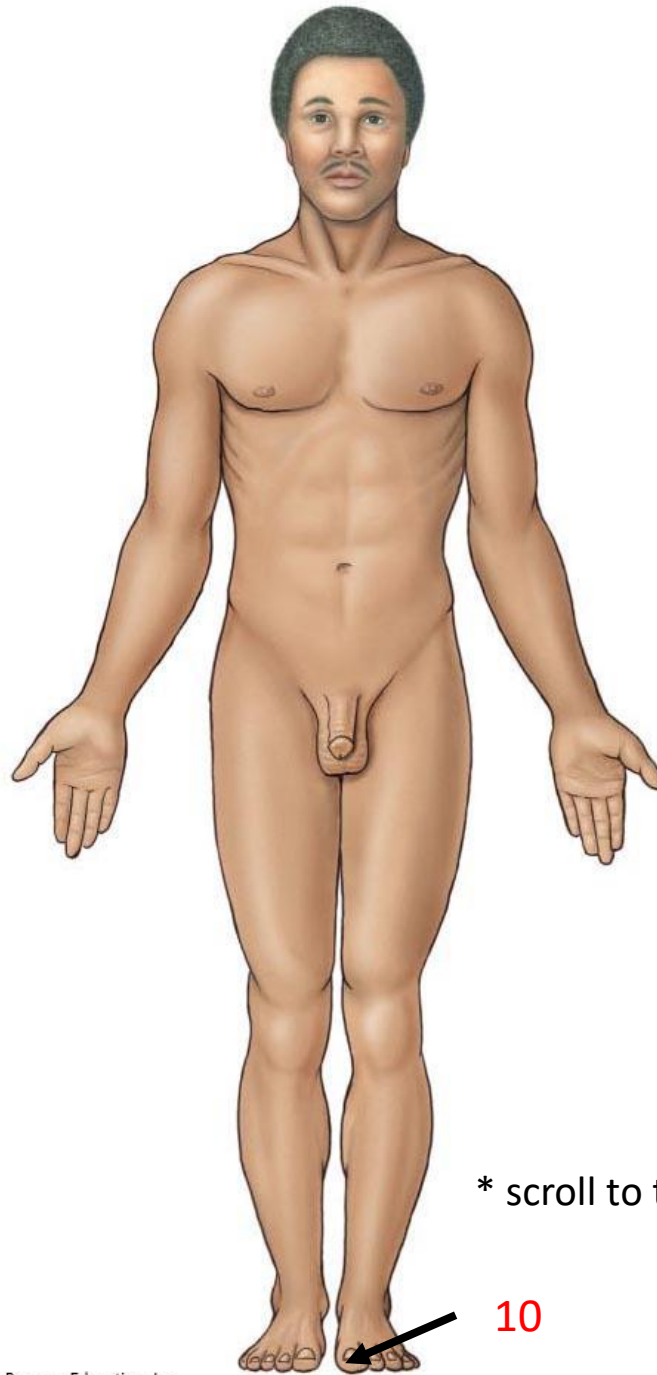


**Antecubital (antecubitus)**



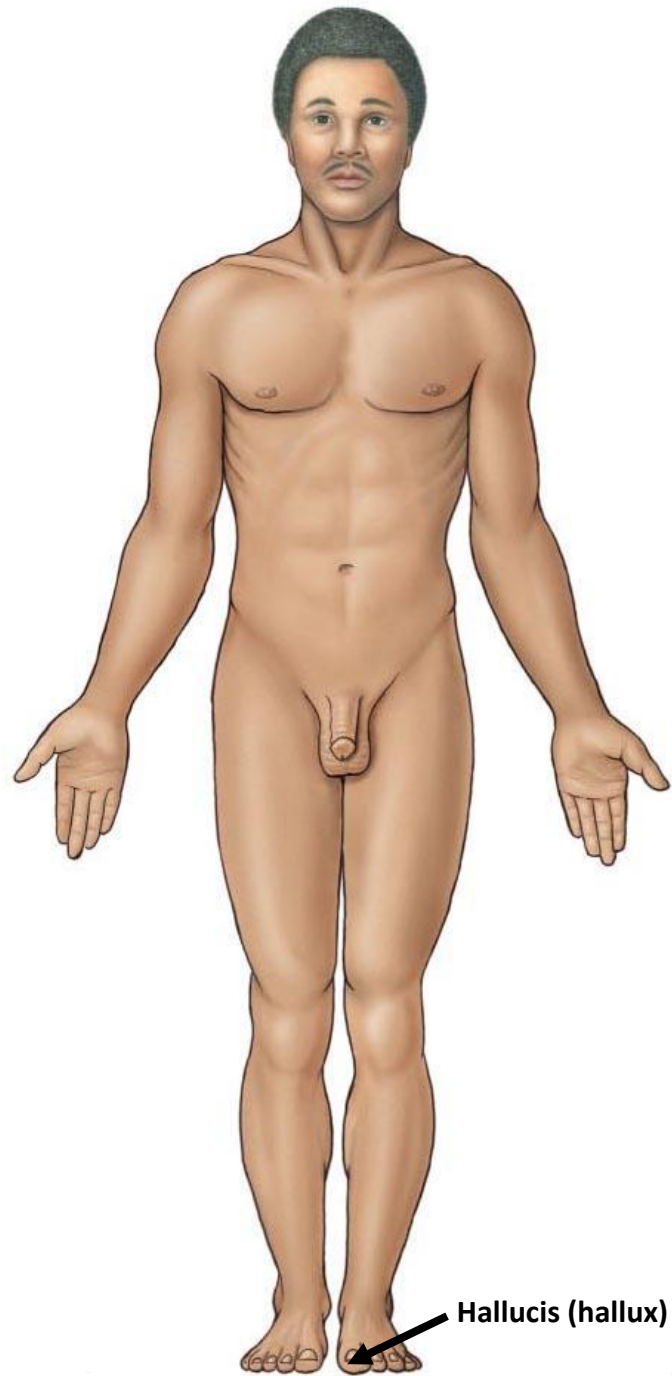


**Femoral (femur)**



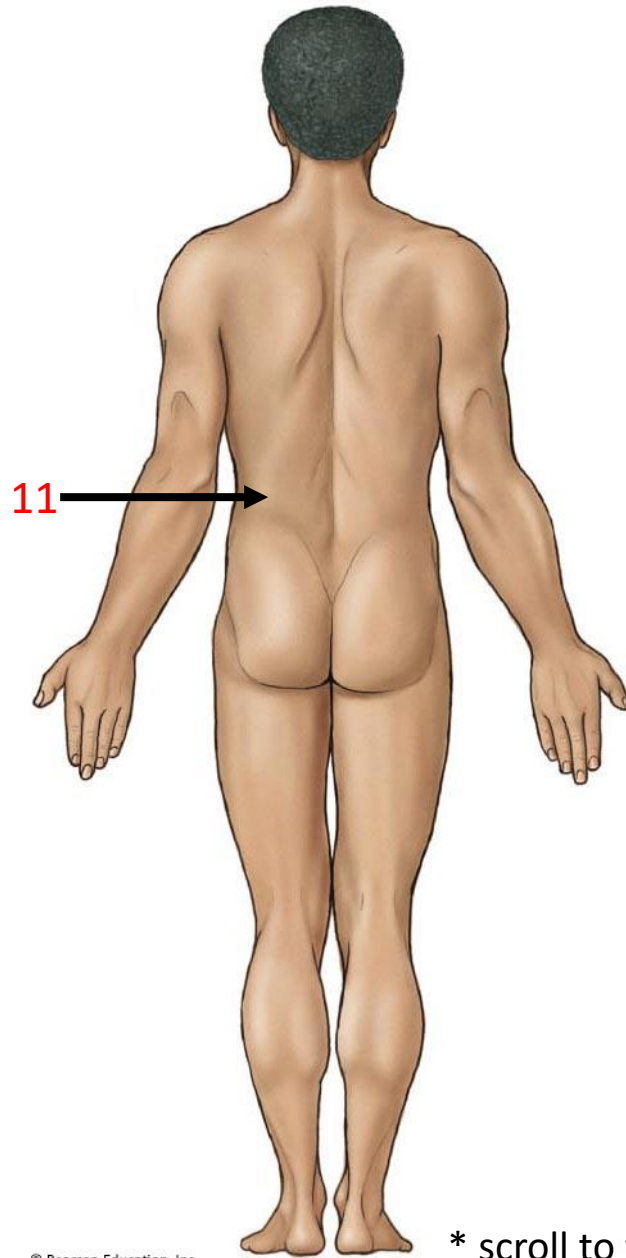
\* scroll to the next slide to check your answer

10

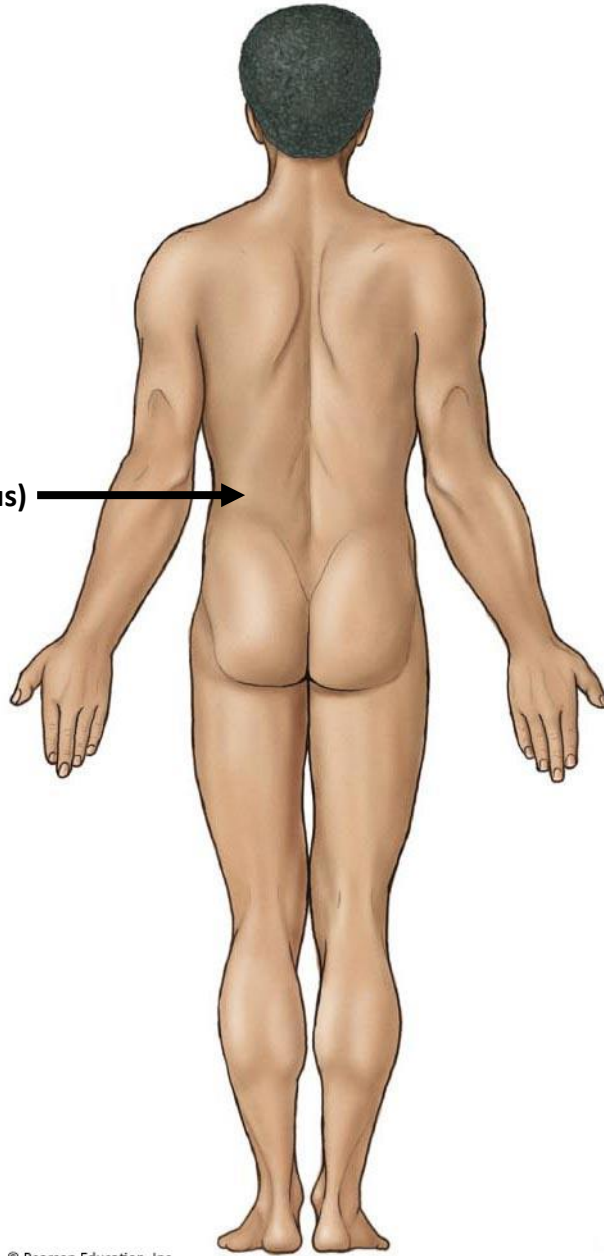


Hallucis (hallux)

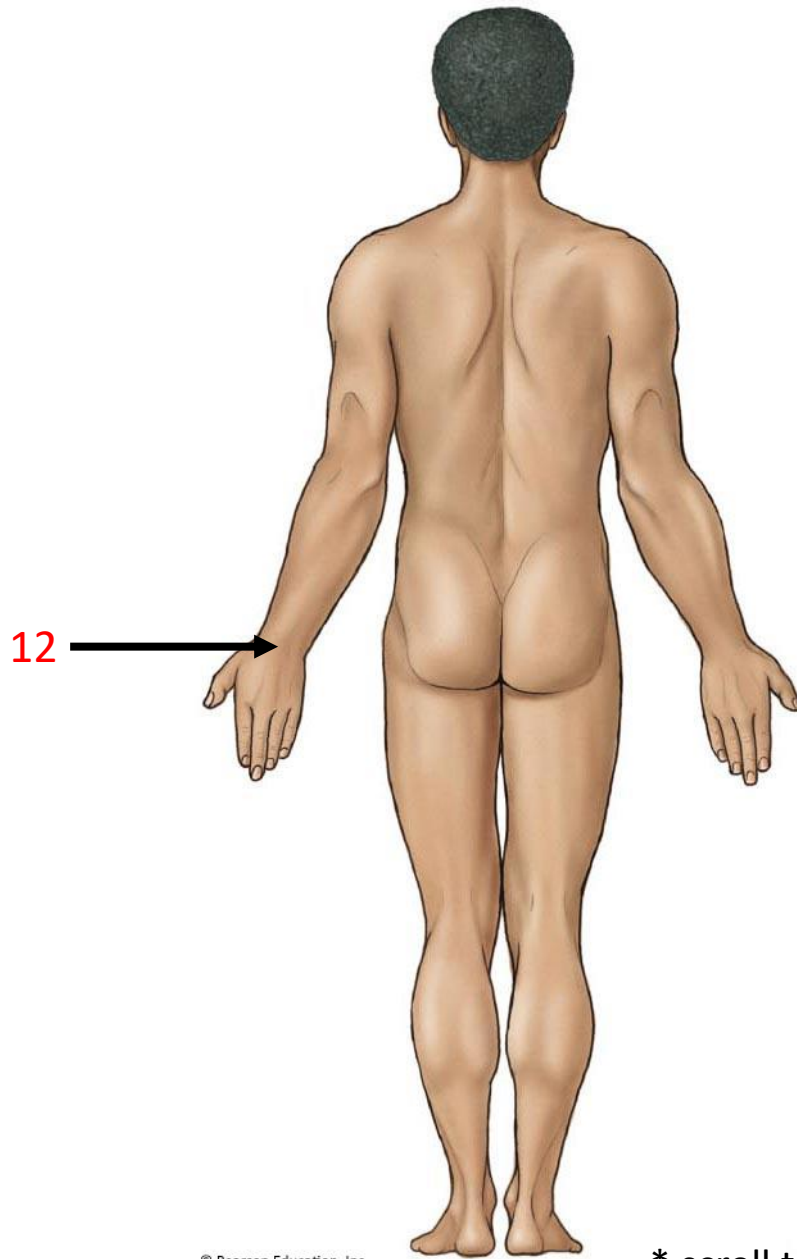




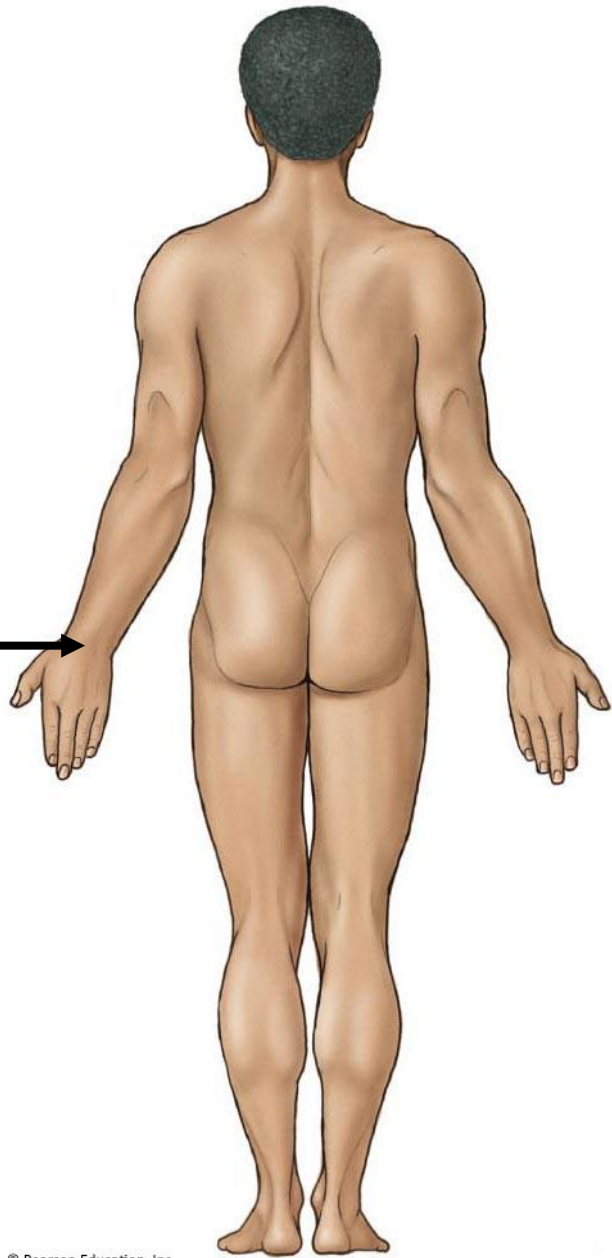
**Lumbar (lumbus)** →

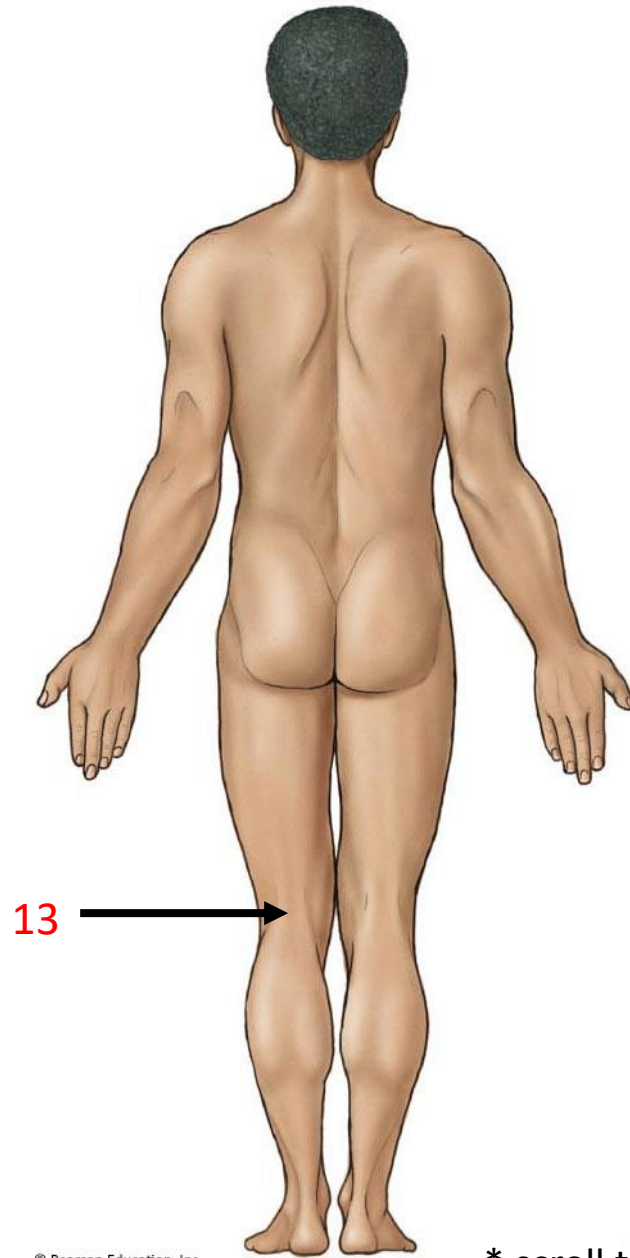


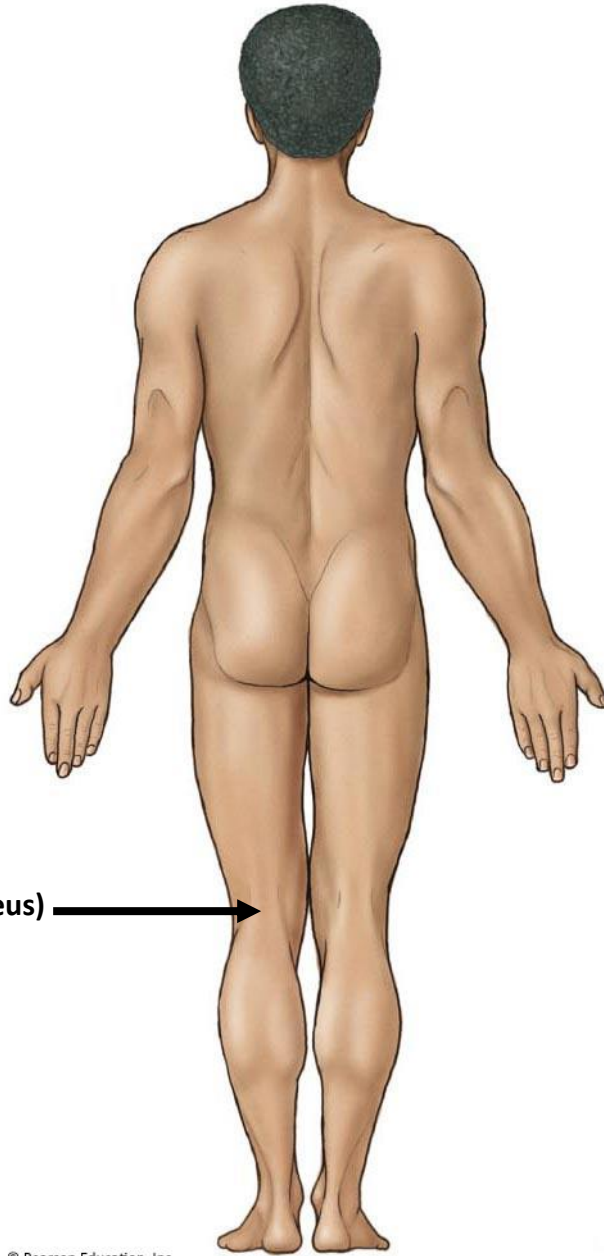




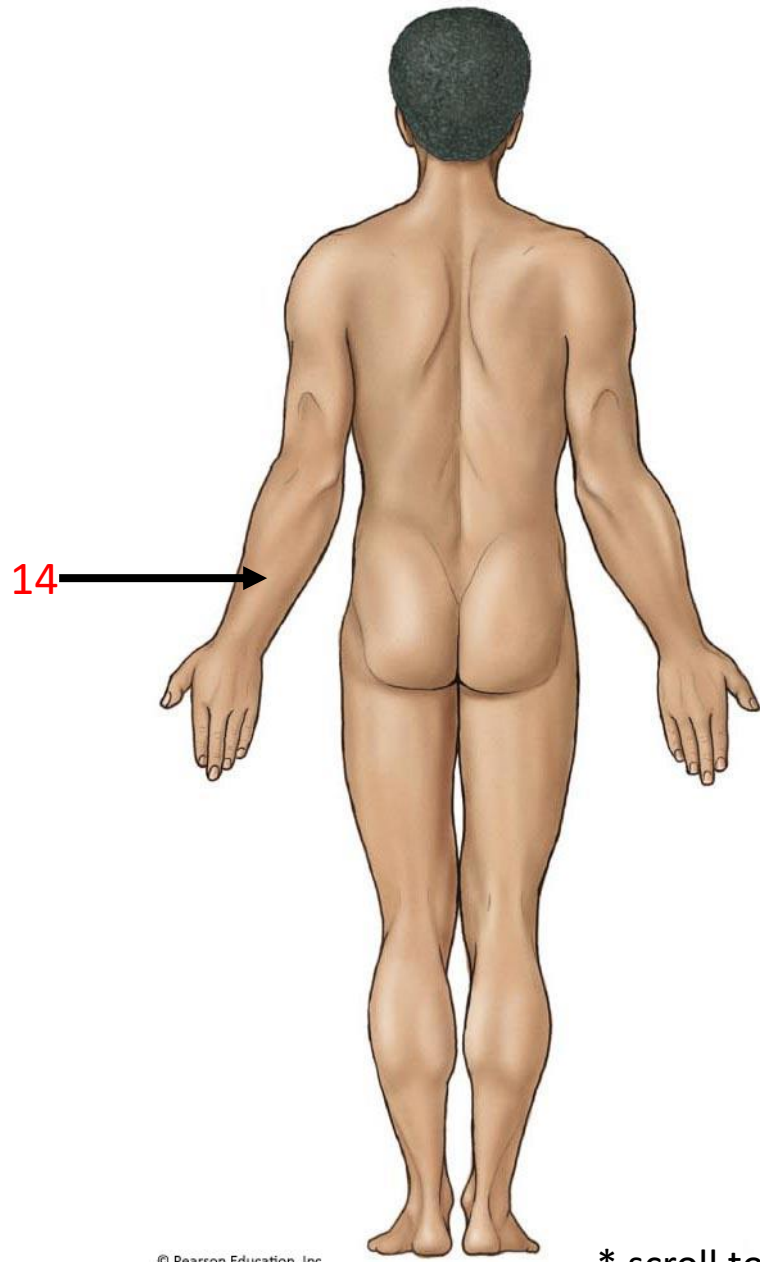
**Carpal (carpus)**



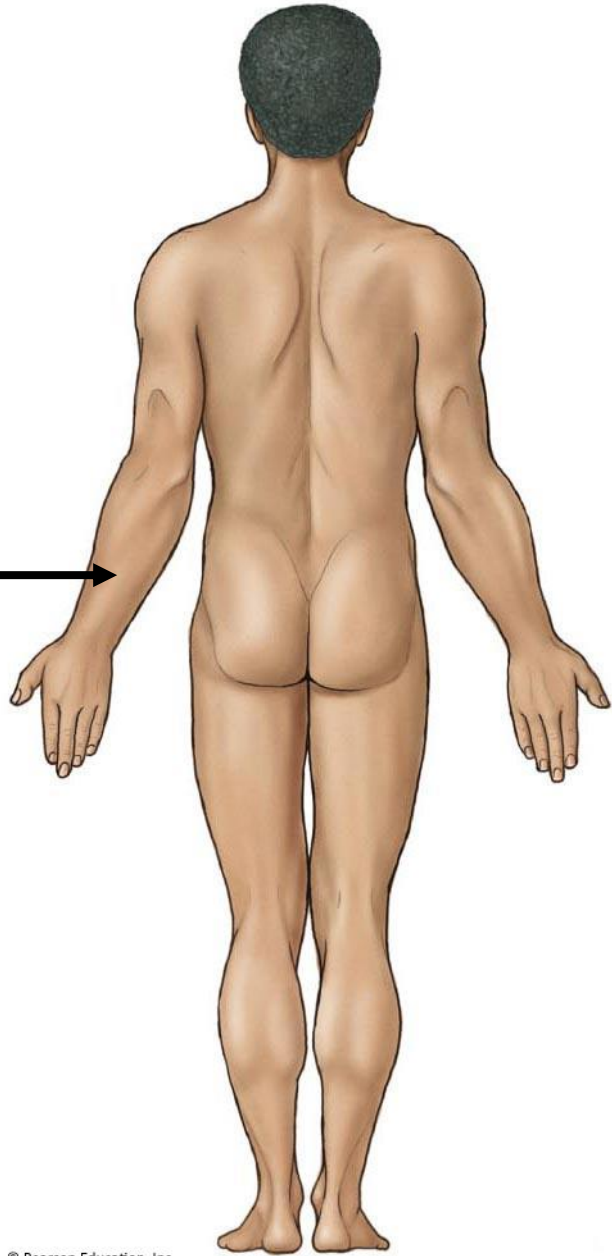


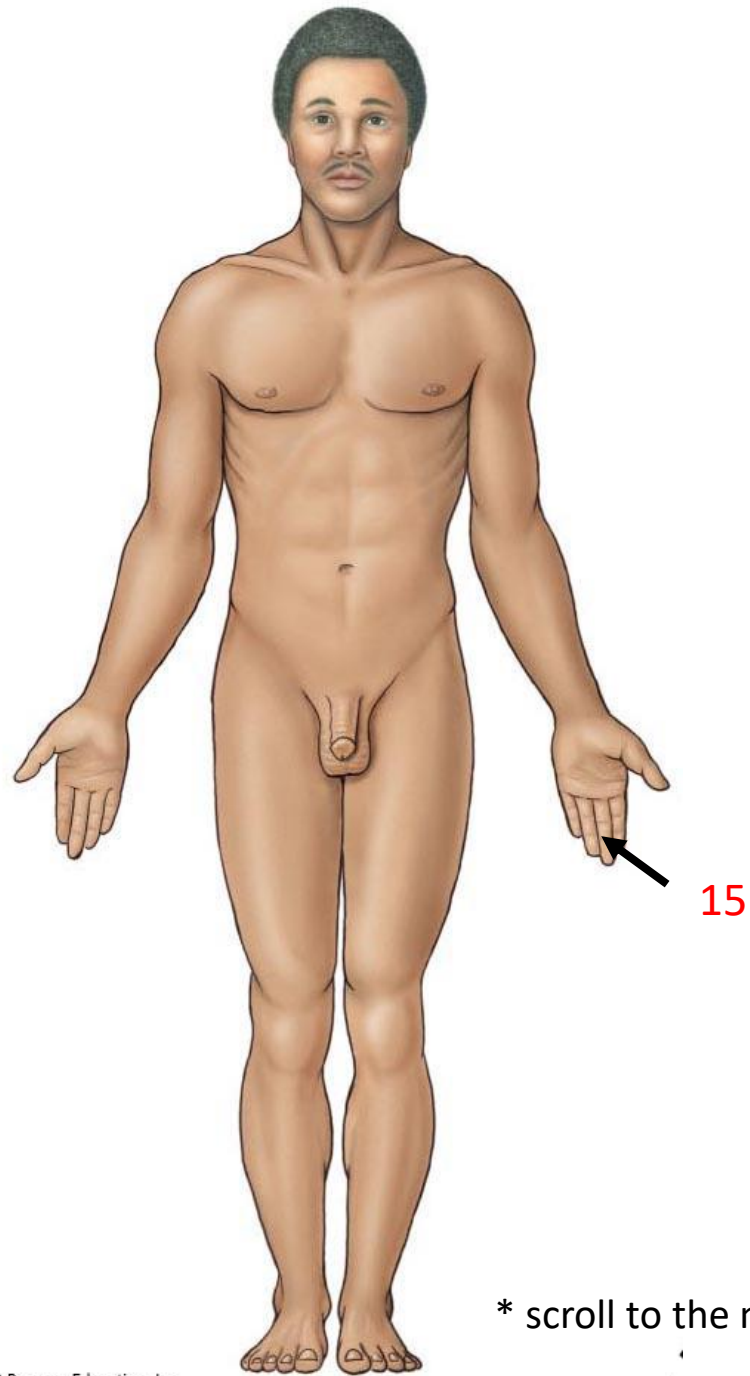

**Popliteal (popliteus)** →

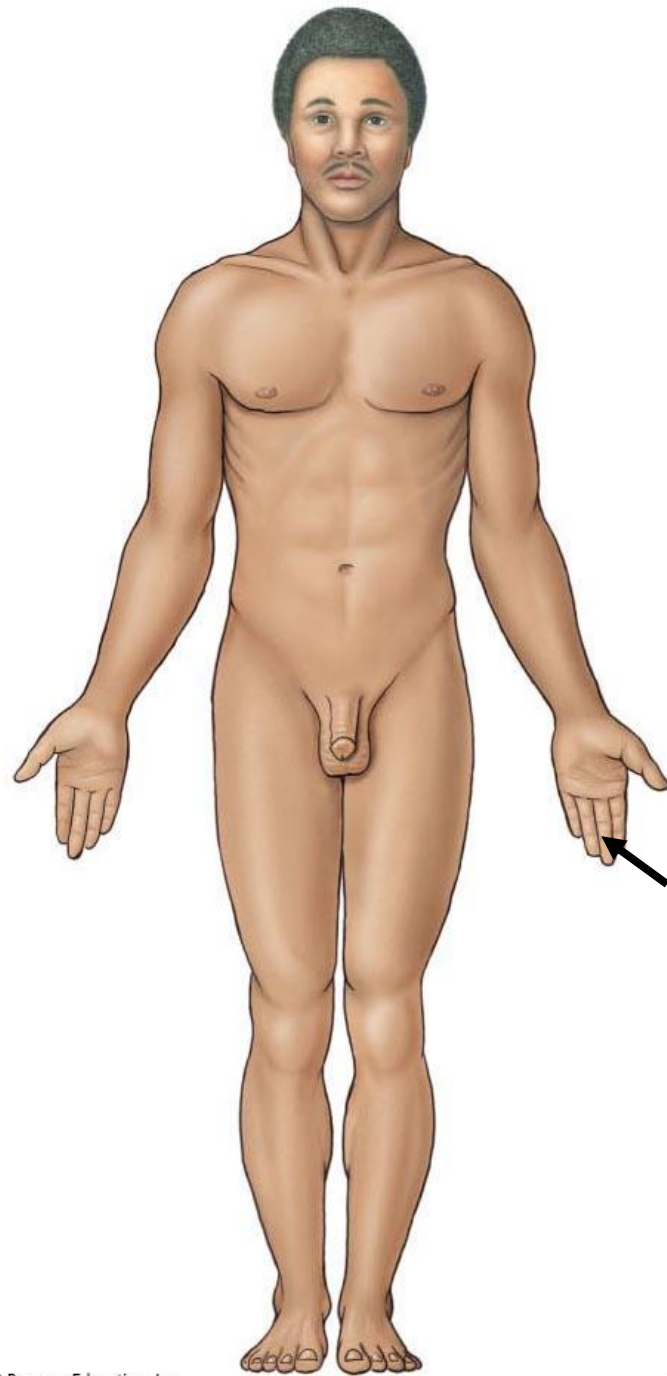


**Antebrachial (antebrachium)** →





\* scroll to the next slide to check your answer



**Digital (digits/phalanges of upper extremity)**